Check for updates

Received: 8 February 2024 | Revised: 6 May 2024 | Accepted: 9 May 2024
DOI: 10.1111/cid.13346

ORIGINAL ARTICLE

WILEY

Autologous bone harvested during implant bed preparation: A randomized clinical trial comparing high-speed drilling with irrigation versus low-speed drilling without irrigation

Juan Carlos Bernabeu-Mira[1] | Miguel Peñarrocha-Diago[1] | Luigi Canullo[2] | Fabio Camacho-Alonso[3] | Arthur Rodriguez Gonzalez Cortes[4] | David Peñarrocha-Oltra[1]

[1]Oral Surgery Unit, Faculty of Medicine and Dentistry, Department of Stomatology, University of Valencia, Valencia, Spain

[2]University of Genova, Genoa, Italy

[3]Department of Oral Surgery, University of Murcia, Murcia, Spain

[4]Faculty of Dental Surgery, Department of Dental Surgery, University of Malta, Valletta, Malta

Correspondence
Juan Carlos Bernabeu-Mira, Faculty of Medicine and Dentistry, Department of Stomatology, University of Valencia, Gascó Oliag 1, 46010, Valencia, Spain.
Email: juan.c.bernabeu@uv.es

Abstract

Objective: To compare collected bone weight and the frequency of autologous bone harvesting from the flutes of surgical drills used for implant bed preparation using two different drilling techniques. A comparative evaluation of radiographic bone density and bone quality was also made.

Materials and Methods: A randomized clinical trial was made of 66 dental implants in patients with a single posterior edentulous site. The compared drilling techniques were high-speed drilling with irrigation (control group) and low-speed drilling without irrigation (test group). The bone collected in both groups was dried and weighed with a precise electronic balance. The frequency of harvesting was calculated. The median radiographic bone density of each implant site was measured using cone-beam computed tomography (CBCT) pixel values. Patient sex, age, implant position and dimensions, as well as the last drill diameter were analyzed as independent variables. The level of significance was 5%.

Results: The harvesting of bone chips from drill flutes proved possible in 51.5% of the procedures in the control group and in 100% in the test group ($p < 0.001$). There were also statistically significant differences in bone weight between the control group (6.7 ± 10.6 mg) and the test group (41.9 ± 30.3 mg) ($p < 0.001$). The CBCT pixel values were directly correlated with the collected bone weight in both groups. The median radiographic bone density, arch and last drill diameter were significantly associated with harvesting bone frequency and collected bone weight ($p < 0.05$).

Conclusions: Our findings suggest that the frequency and weight of autologous bone harvested from drills are greater with low-speed drilling without irrigation than with high-speed drilling with irrigation. Radiographic bone density, arch and last drill diameter also significantly influenced the harvesting outcomes.

KEYWORDS
autologous bone, biological drilling, bone quality, density, dental implant, harvested bone, low-speed drilling, osteotomy

This is an open access article under the terms of the Creative Commons Attribution License, which permits use, distribution and reproduction in any medium, provided the original work is properly cited.
© 2024 The Author(s). *Clinical Implant Dentistry and Related Research* published by Wiley Periodicals LLC.

Summary box

What is known

A recent systematic review showed a low percentage of clinical human studies on low-speed drilling without irrigation. Only one in vitro study analyzed harvested autologous bone comparing the two drilling techniques, and a high risk of bias was determined.

What this study adds

The present study is the first randomized controlled clinical trial on this topic and improves planning of the amount and rate of autologous bone collection according to the drilling technique employed. This could favor regeneration techniques without opening a second surgical area for small size defects.

1 | INTRODUCTION

Oral rehabilitation with dental implants has been considered a treatment option with a high long-term success rate.[1] The main factors reported to influence the success of implant therapy include alveolar bone quality, dental implant surface treatment and geometry, and the surgical technique used.[2] In this regard, bone overheating during drilling may lead to the failure of osseointegration due to thermal osteonecrosis.[3]

The use of irrigation during implant drilling has become the most common technique to prevent bone from overheating.[4] However, bone overheating is a multifactorial phenomenon.[5,6] Among the possible causes are a lack of irrigation and excessive drilling speed. A new technique known as low-speed drilling without irrigation has been described in dental implantology for implant site preparation.[7] This technique involves rotational drilling speeds ranging from 45 to 200 rpm without irrigation.[8]

Concerns about possible osteonecrosis due to a lack of irrigation during drilling do not seem to be supported by scientific evidence. Several in vitro studies comparing conventional and low-speed drilling without irrigation[7,9–12] have shown that both techniques maintain the critical threshold temperature below 47°C for 1 min.[3] Additionally, similar implant success rates and marginal peri-implant bone loss were reported for both techniques[13,14] with follow-up periods ranging from 6 to 12 months.

Several studies have described greater cellularity of the harvested autologous bone with low-speed drilling without irrigation.[7,15,16] However, according to a recent systematic review,[8] no clinical study to date has quantified the frequency with which bone harvesting from implant drill flutes is possible or compared the conditions of the autologous bone harvested from the drills after implant site drilling. Recent research has suggested the physiological effects of cellular apoptosis after autologous bone harvesting using conventional drills (animal model study in rats).[17,18] Even though the aforementioned studies were not conducted in humans, it would be plausible to assume that smaller particles (from drilling) present lower cellularity, and this is perhaps why greater cellular apoptosis and cellular death may be observed. Particle size may have an impact upon osteogenic potential.[19,20] The results suggested that larger bone graft particles produced by bone milling and bone scraper techniques have a greater osteogenic potential than bone slurry and the use of piezoelectric surgery. However, the drilling procedures in the mentioned studies involved high-speed drilling with irrigation, and the bone was harvested from an aspirator.

Guided bone regeneration has proven to be an effective treatment approach for enhancing the alveolar ridge.[21] Various grafting biomaterials combined with a barrier membrane to create space and provide a scaffold have been applied.[22] Autogenous bone has been described as the "gold standard" due to its osteogenic and osteoinductive properties.[23] Such autogenous bone has clinically demonstrated good long-term volume maintenance.[24-26] In other cases, a combination of autogenous bone and allogenic or xenogenic bone substitutes has been introduced for the treatment of vertical or horizontal defects.[27-29] Autogenous bone from low-speed drilling without irrigation could be sufficient for bone regeneration in small bone defects or in some types of buccal gaps of extraction sockets, without the need for a second intraoral donor site.

One of the most important factors concerning bone harvesting is bone density. The most widely used bone quality classification is the Lekholm and Zarb scale.[30] The scale relies on the conditions of cortical and trabecular bone areas on two-dimensional radiographs. This scale was further developed by Misch et al., who added the subjective tactile perception obtained by the operator during implant site drilling.[31] However, the aforementioned evaluations did not include any three-dimensional quantitative analyses. Subsequently, Norton and Gamble[32] established quantitative Hounsfield Unit (HU) ranges on medical computed tomography (CT) images that were correlated to the types of bone described in the Lekholm and Zarb classification. Although true HU is not compatible with cone-beam computed tomography (CBCT), previous studies described the use of the original CBCT pixel values taken from implant sites as a measurement directly proportional to alveolar bone density, as demonstrated by correlations with histological and morphometric findings.[33,34] This measurement has been referred to as "radiographic bone density."

The purpose of the present study was to quantify the frequency of bone harvesting and bone content in the flutes of surgical drills

17088208, 2024, 4, Downloaded from https://onlinelibrary.wiley.com/doi/10.1111/cid.13346 by Dr. Juan Carlos Bernabeu-Mira - Universitat De Valencia , Wiley Online Library on [06/10/2025]. See the Terms and Conditions (https://onlinelibrary.wiley.com/terms-and-conditions) on Wiley Online Library for rules of use; OA articles are governed by the applicable Creative Commons License

after implant bed preparation using high-speed drilling with irrigation and low-speed drilling without irrigation. The influence of bone density and bone quality on harvesting frequency and weight was analyzed. The null hypothesis was that there would be no statistically significant differences between the two groups.

2 | MATERIALS AND METHODS

2.1 | Study design

The present article describes the assessment of exposure variables of a study, as part of a series of papers. The primary outcome is mean marginal bone loss and will be reported in a subsequent publication as soon as the follow-up period has been completed.

The present randomized, controlled single-blind clinical trial was conducted between February 2022 and June 2022 in the Oral Surgery Unit (Faculty of Medicine and Dentistry, University of Valencia, Valencia, Spain). The research was conducted following the principles described in the Declaration of Helsinki and was approved by the Ethics Committee of the University of Valencia (reference code: 1937615). The study was registered in ClinicalTrials.gov (NCT05 286866). The CONSORT guidelines were followed.[35]

The placement of only one posterior single-tooth dental implant was considered per patient. Implant site osteotomies were randomly allocated to two groups: a control group subjected to high-speed drilling (800 rpm) with irrigation, and a test group subjected to low-speed drilling (150 rpm) without irrigation.

2.2 | Participants

The patient inclusion criteria were as follows: (1) single posterior edentulism, (2) patients who have completed the growth phase, (3) plaque and bleeding index <25% throughout the mouth, (4) sufficient height and width of bone for the placement of a dental implant (4 mm in diameter and 8–10 mm in length) without bone regeneration procedures, (5) keratinized mucosa of at least 2 mm around the dental implant, (6) stable occlusion and a healthy periodontium, (7) no medical conditions contraindicating implant surgery, such as heavy smoking (>10 cigarettes per day), severe bruxism, pregnant or breastfeeding patients, bisphosphonate therapy, patients receiving chemotherapy and radiation therapy to the head and/or neck, and (8) uncooperative patients. The exclusion criteria were: (1) loss of the sample during transfer from the drill to the test tube or (2) contamination of the sample by other substances.

2.3 | Interventions

Firstly, each included patient underwent an anamnesis, oral examination and preoperative panoramic radiographic study. A radiological splint with a radiopaque marker at the implant site was fabricated, and a CBCT scan was performed with it.

Each patient underwent prophylactic hygiene 7 days before the intervention, and 2 g of oral amoxicillin was prescribed 1 h before the intervention as prophylactic medication. All surgeries were performed by the same experienced operator (Juan Carlos Bernabeu-Mira). The placed implants were IPX (Nueva Galimplant S.L, Sarria, Galicia, Spain), 4 mm in diameter and 8–10 mm in length, placed 2 mm subcrestally. Surgical drills with stops (K Fres Stop, Nueva Galimplant S.L, Sarria, Spain) were used to prepare the osteotomies with continuous drilling without pumping. A drill 2 mm longer than the implant length was used to ensure the 2 mm subcrestal implant position. A total of five surgical drills were used: pilot, 2, 2.6, 3.2, and 3.6 mm in diameter. The pilot drill was used at 1200 rpm with irrigation in both groups. The following subsequent drill speeds were used: 800 rpm in the control group (high-speed drilling with irrigation) and 150 rpm in the test group (low-speed drilling without irrigation). The rotatory movement of the drill was stopped until the drill was fully outside the implant bed in both groups. Two-millimeter high antirotational one-piece abutments were placed immediately after implant insertion; thus, healing was non-submerged.

Autologous bone was harvested from the flutes of the surgical drills. A small periostotome was used to transfer the bone to the test tubes. The bone harvested from each surgical drill in the drilling sequence was added to the same test tube. The samples were immediately stored at a controlled temperature of −20°C in a freezer.

Postoperative instructions were explained to the patients. The sutures were removed 7 days after surgery. Prosthetic loading was performed 10 weeks after implant placement.

2.4 | Outcome variables

2.4.1 | General variables

Sex (male or female), age, implant position (premolar or molar), arch (upper or lower), implant dimensions (4 × 8 or 4 × 10 mm), and last drill (3.2 or 3.6 mm in diameter) were recorded.

2.4.2 | Harvesting frequency

A binary assessment (yes or no) was used to calculate the frequency of implant sites in which autologous bone harvesting from drill flutes proved possible, in each group.

2.4.3 | Weight of autologous bone

To eliminate the risk of bias from saline solution or blood, which could alter the weight of the samples, a drying procedure was used. Each sample was placed in a laboratory dryer (Digitheat-TFT, JP SELECTA, Barcelona, Spain) at 40°C for 24 h. This drying process eliminated the risk of bias. A laboratory precision scale (Explorer analytical, OHAUS, Nänikon, Switzerland) was used to measure the weight of the bone.

17088208, 2024, 4, Downloaded from https://onlinelibrary.wiley.com/doi/10.1111/cdd.13346 by Dr. Juan Carlos Bernabeu-Mira - Universitat De Valencia , Wiley Online Library on [06/10/2026]. See the Terms and Conditions (https://onlinelibrary.wiley.com/terms-and-conditions) on Wiley Online Library for rules of use; OA articles are governed by the applicable Creative Commons License

FIGURE 1 Surgical drills after low-speed drilling without irrigation showed different radiographic bone densities after implant bed preparation. (A) High bone density: surgical drill is full of bone, appearing white without blood; (B) Medium bone density: surgical drill is almost full of bone, but appearing red with blood; (C) Low bone density: surgical drill is nearly empty of bone, with a red appearance due to presence of blood.

For each sample, the bone from the test tubes were transferred to another new tared test tube. The weight of autologous bone was correlated with the radiographic bone density to provide presurgical information to the clinician about the quantity of bone that could be harvested according to the observed radiographic bone density.

2.4.4 | Radiographic bone density measurement and bone quality assessment

Radiographic bone density measurements were made following the protocol described by Turkyilmaz et al.[36] The implant site was determined using a radiopaque marker on the radiological splint. The region corresponding to the last surgical drill was carefully recorded. The assessment of radiographic bone density was performed using Newtom software (Cefla S.C, Bologna, Italy), and the results were given as CBCT pixel values expressed using Hounsfield Units (HU) just as an output unit, following previous methodologies.[33,34] Following previously described methods,[37] bone quality was evaluated according to the Lekholm and Zarb classification[30] after assessing the cross-sectional images from the CBCT scan (Figure 1).

2.5 | Randomization, allocation and blinding

The patients were randomized before the surgical procedure using simple randomization via www.randomization.com. This was a randomized, single-blind clinical trial in which both the operator and the patient were aware of the assigned study group. However, data collection and data analysis were conducted in a blinded manner. Random allocation codes were sealed within sequentially numbered opaque envelopes. The concealment of allocation was disclosed after flap lifting, when the corresponding envelope was opened, and the operator was informed whether to proceed with drilling at 800 rpm with irrigation or at 150 rpm without irrigation.

2.6 | Statistical analysis

Descriptive and inferential analyses were conducted for each variable. Additionally, a mixed linear regression model was applied. To assess homogeneity between groups at both the patient and implant levels, the chi-square test and Mann–Whitney *U*-test were employed. Data were analyzed assuming a nonparametric distribution, as determined by the Kolmogorov–Smirnov test. The Mann–Whitney *U*-test was used to compare distributions related to nonparametric variables, such as bone weight. The chi-square test and Fisher's exact test were used to evaluate associations between two categorical variables. Spearman's coefficient was used to analyze nonlinear correlations among non-ordinal parameters. Simple linear regression was used to analyze the correlation between mean bone density and bone weight in the test group. Spearman's assessment was applied to correlate mean radiographic bone density and bone weight in the control group. The significance level was set at 5% ($\alpha = 0.05$).

3 | RESULTS

The present study included a total of 66 patients, 33 women and 33 men, with ages ranging from 21 to 75 years (mean 54.5 ± 14.4). Homogeneity between both groups was observed for each variable, including sex, age, arch, position, implant dimension, last drill diameter, and bone density ($p > 0.05$). Descriptive and analytical data are presented in Table 1. The participant flow is represented in Figure 2.

Bone harvesting proved possible in 51.5% of the implant sites in the control group and in 100% of the implant sites in the test group—the difference between groups being statistically significant ($p < 0.001$). The upper arch exhibited a lower harvesting frequency (64.5%) compared to the lower arch (85.7%) ($p < 0.05$). Statistically significant differences ($p < 0.05$) were also observed between the groups in relation to the final drill diameter, with a harvesting frequency of 64.1% for the 3.2 mm diameter and 92.6% for the 3.6 mm

17088208, 2024, 4, Downloaded from https://onlinelibrary.wiley.com/doi/10.1111/cdd.13346 by Dr. Juan Carlos Bernabeu-Mira - Universitat De Valencia , Wiley Online Library on [06/10/2025]. See the Terms and Conditions (https://onlinelibrary.wiley.com/terms-and-conditions) on Wiley Online Library for rules of use; OA articles are governed by the applicable Creative Commons License

TABLE 1 Descriptive data for different variables at patient level. Homogeneity, effect of independent variable and statistical test.

		Control	Test	Sample homogeneity		Effect of independent variable	
Variable	Categories	*n* (%) or Δ ± SD	*n* (%) or Δ ± SD	*p* value	Statistical test	Rate; *p* value (statistical test)	Weight; *p* value (statistical test)
Sex	Male	17 (51.5)	16 (48.5)	0.806	Chi^2	0.251 (Chi^2)	0.106 (Chi^2)
	Female	16 (48.5)	17 (51.5)				
Age	–	53 ± 14.5	56 ± 14.4	0.422	MW	0.305 (MW)	0.845 (Spearman)
Arch	Upper	15 (45.5)	16 (48.5)	0.805	Chi^2	0.045 (Chi^2)	0.052 (MW)
	Lower	18 (54.5)	17 (51.5)				
Position	Premolar	20 (60.6)	21 (63.6)	0.800	Chi^2	0.971 (Chi^2)	0.878 (MW)
	Molar	13 (39.4)	12 (36.4)				
Implant dimension	4 × 8 mm	17 (51.5)	18 (54.5)	0.805	Chi^2	0.383 (Chi^2)	0.105 (MW)
	4 × 10 mm	16 (48.5)	15 (45.5)				
Last drill diameter	3.2 mm∅	20 (60.6)	19 (57.6)	0.802	Chi^2	0.008 (Chi^2)	<0.001 (MW)
	3.6 mm∅	13 (39.4)	14 (42.4)				
Bone density	–	739.3 ± 328.6	723.3 ± 319.3	0.724	MW	$p < 0.001$ (MW)	$p < 0.001$ (Spearman)

Abbreviation: MW, Mann–Whitney *U*-test.

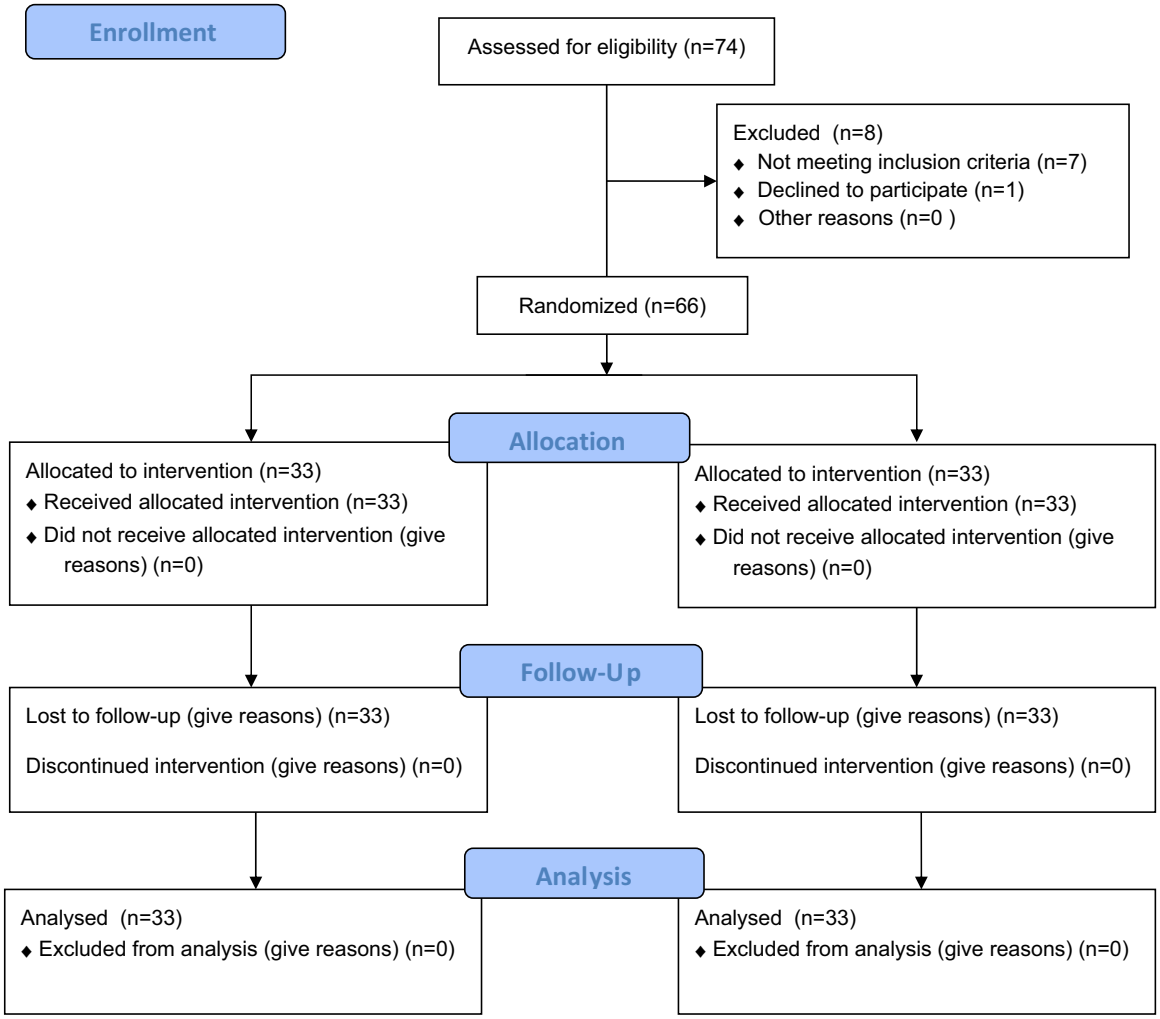

FIGURE 2 Consort flow chart.

17088208, 2024, 4, Downloaded from https://onlinelibrary.wiley.com/doi/10.1111/cdd.13346 by Dr. Juan Carlos Bernabeu-Mira - Universitat De Valencia , Wiley Online Library on [06/10/2026]. See the Terms and Conditions (https://onlinelibrary.wiley.com/terms-and-conditions) on Wiley Online Library for rules of use; OA articles are governed by the applicable Creative Commons License

TABLE 2 Bone quality classification according to Lekholm and Zarb and its influence upon the bone harvesting rate and bone weight in the two groups.

	Lekholm and Zarb classification			
	D1	D2	D3	D4
Bone harvesting rate (%)				
Control group	100	91.7	35.7	0
Test Group	100	100	100	100
Bone weight (mg)				
Control group	27.7 ± 0.0	14.1 ± 12.6	1.6 ± 3.1	0 ± 0
Test Group	105.4 ± 2.4	60.3 ± 23.9	35 ± 21.6	6.4 ± 7.6

diameter. The mean radiographic bone density significantly influenced the frequency of collected bone ($p < 0.001$). Furthermore, the frequency of bone harvesting was significantly influenced by bone quality (Table 2). According to the Lekholm and Zarb classification, harvesting frequency exhibited a decreasing pattern from D1 (100%) to D2 (95%), D3 (72.7%), and D4 (40%), with statistically significant differences ($p < 0.01$). While the test group achieved a harvesting frequency of 100%, the statistically significant differences were associated with the control group ($p < 0.001$). For bone qualities D3 and D4, the test group showed an increased frequency of bone harvesting with statistically significant differences versus the control group ($p < 0.05$).

The mean weight of harvested bone was 6.7 ± 10.6 mg in the control group and 41.9 ± 30.3 mg in the test group – the difference between groups being statistically significant ($p < 0.001$). Likewise, significantly different results ($p < 0.001$) were observed between groups regarding bone weight in relation to the final drill diameter, with median values of 5 and 31.4 mg for the 3.2 and 3.6 mm diameters, respectively. The mean radiographic bone density significantly influenced the weight of collected bone ($p < 0.001$). Additionally, bone weight was influenced by bone quality. According to the Lekholm and Zarb classification (Table 2), statistically significant differences were found for different bone qualities ($p < 0.01$). Bone weight exhibited a proportional increase relative to the radiographic bone densities ($p < 0.01$), and the test group yielded a higher bone weight than the control group, with statistically significant differences being observed for each bone quality level ($p < 0.01$). Regarding the correlation between the mean radiographic bone density and bone weight, the test group showed a clearly linear relationship of a strong and significant magnitude ($r = 0.82$; $p < 0.001$). A simple linear regression model estimated beta = 0.078 (95%CI: 0.058–0.098) ($p < 0.001$). Each additional unit of mean HU implied an increase of 0.078 mg in bone weight. In the control group, the relationship was found to be nonlinear and of a strong and significant magnitude (Spearman $r = 0.71$; $p < 0.001$) (Figure 3).

4 | DISCUSSION

The present study compared the conditions of autologous bone chips harvested from drill flutes after implant site drilling using two different drilling speed protocols. The bone harvesting frequency and bone weight were significantly higher with low-speed drilling without irrigation compared to conventional drilling. Mean bone density and bone quality also significantly influenced the frequency of harvesting and mean weight in both groups.

To the best of our knowledge,[8] only one study to date has compared the amount of bone collected with high-speed drilling with irrigation versus low-speed drilling without irrigation. However, the mentioned article was an in vitro study with a limited sample size (total sample size of 30).[38] The results obtained are consistent with those of the present study, showing that standard drilling resulted in less volume of bone compared to low-speed drilling without irrigation. However, there are also articles that compare autologous bone collected with different methods other than drilling of the implant bed.[39-42]

Clinically, the low-speed technique has demonstrated a high implant success rate similar to that obtained with standard drilling.[13,14] Regarding marginal bone loss, three randomized clinical trials[13,14] have reported no statistically significant differences between high-speed drilling with irrigation and low-speed drilling without irrigation, over follow-up periods ranging from 6 to 12 months. Thus, the harvesting of autologous bone could be an advantage of low-speed drilling without irrigation.

Autologous bone is considered to be the gold standard for bone regeneration techniques.[43] Several clinical studies have demonstrated the potential advantages of autologous bone harvested using low-speed drilling without irrigation compared to high-speed drilling with irrigation.[7,15,16] It is important to mention a crucial aspect regarding the bone harvesting process for each drilling technique. Some studies[7,15] did not directly harvest bone from the drill flutes in low-speed drilling without irrigation; instead, they used a filter in the aspiration system for high-speed drilling with irrigation. This approach may introduce a risk of bias in the histological and cellular analysis, indirectly indicating the challenges of harvesting bone in high-speed drilling with irrigation. Two studies[7,44] that used the filtering process could not perform a cellular analysis due to the lack of cellularity in the high-speed drilling with irrigation group. The only study[16] that directly collected bone from the flutes with both drilling techniques described a higher proliferation and differentiation rate with low-speed drilling compared to conventional drilling. Direct harvesting of bone from the surgical drills was the selected method for both drilling techniques in the present study.

The use of irrigation and high revolutions per minute during osteotomy may remove the protein layer and signaling factors in

17088208, 2024, 4, Downloaded from https://onlinelibrary.wiley.com/doi/10.1111/cdd.13346 by Dr. Juan Carlos Bernabeu-Mira - Universitat De Valencia , Wiley Online Library on [06/10/2025]. See the Terms and Conditions (https://onlinelibrary.wiley.com/terms-and-conditions) on Wiley Online Library for rules of use; OA articles are governed by the applicable Creative Commons License

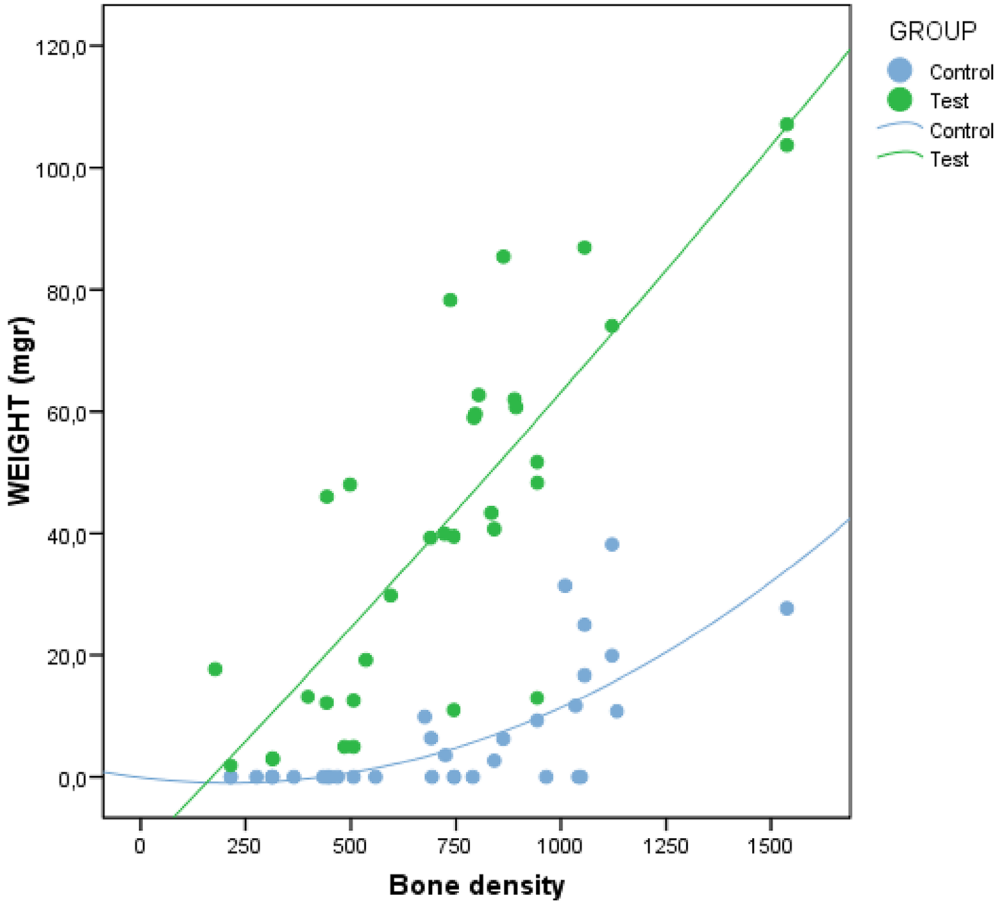

FIGURE 3 Correlation between radiographic bone density and bone weight.

bone, eliminating living cells.[15,16] The difficulty or impossibility of harvesting bone with high-speed drilling and irrigation may be due to the greater centrifugal force of high revolutions per minute and the profuse irrigation. These factors can dislodge bone from surgical drills. In the present study, conventional drilling allowed bone harvesting in 51.5% of the sample, while 100% of the sample harvested bone with low-speed drilling without irrigation.

A negative impact on patient quality of life due to two open surgical fields has also been reported.[45] For relatively small bone defects, autologous bone harvested during low-speed drilling without irrigation may be the best option. In the present study, low-speed drilling without irrigation yielded an average autologous bone weight of 41.9 ± 30.3 mg. Moreover, prior to surgery, the clinician could calculate the amount of autologous bone according to the correlation between bone weight and bone density in pixel values, which were expressed using HU solely as output units. However, not every socket requires grafting. Research has shown that non-grafted sockets present a significant osteogenic potential, and well performed extractions can lead to dehiscence self-repair and new buccal bone formation even at sites presenting >5 mm of facial bone dehiscence.[46]

One of the most important aspects of autogenous bone is its capacity to induce new bone formation through the shedding of new osteoblasts and growth factors (BMP-2, VEGF) from the freshly harvested particles. Autologous bone harvesting through low-speed drilling possibly does not affect such shedding from the bone particles to any great extent.[20] Moreover, particle size may have an impact on osteogenesis. The bone slurry (average particle size 0.2 mm) from the implant drilling osteotomy seems to have a significantly lower osteogenic potential than larger size particles (>0.5 mm: mean 1.5–2 mm) harvested with a bone scraper, for instance.[19] Research has shown significantly lower or no release of growth factors, and lesser cell viability, with bone harvested from implant osteotomy drilling. Larger bone particles (bone scraper harvesting) have a significantly greater osteogenic potential.

Clinically, the consistency and handling properties of autogenous bone harvested with a scraper make it superior to bone harvested through drilling, with addition of the aforementioned benefits as well (greater cell viability and release of growth factors).[19,20] This underscores the importance of selecting the most effective and beneficial harvesting method in order to optimize patient outcomes in regenerative procedures. Opting for a harvesting technique that yields superior regenerative results could potentially enhance the overall success and efficacy of the regenerative process.

Future studies on the topic should calculate sample size using harvested bone as the primary variable. Furthermore, different drill designs can have a significant impact on the outcomes of the study. Thus, if osteotomies were performed in posterior areas, a low number of osteotomies would be drilled in type D1 bone. Randomized clinical trials involving simultaneous regenerative processes may be necessary to apply this quantity of harvested autologous bone around implant defects.

17088208, 2024, 4, Downloaded from https://onlinelibrary.wiley.com/doi/10.1111/cdd.13346 by Dr. Juan Carlos Bernabeu-Mira - Universitat De Valencia , Wiley Online Library on [06/10/2026]. See the Terms and Conditions (https://onlinelibrary.wiley.com/terms-and-conditions) on Wiley Online Library for rules of use; OA articles are governed by the applicable Creative Commons License

5 | CONCLUSIONS

Within the limitations of the present study, the harvesting frequency and weight of autologous bone were greater with low-speed drilling without irrigation compared to high-speed drilling with irrigation. The results also indicated that bone density and bone quality proportionally influence the frequency and weight of the harvested bone. The mandible and a greater final diameter of the drill were also significantly associated to greater harvesting frequency and weight. Nevertheless, additional clinical studies are needed to confirm these findings.

AUTHOR CONTRIBUTIONS

Conception and design of the study: Juan Carlos Bernabeu-Mira, Miguel Peñarrocha-Diago, Luigi Canullo, Fabio Camacho-Alonso, Arthur Rodriguez Gonzalez-Cortes and David Peñarrocha-Oltra. Performing surgeries and prostheses: Juan Carlos Bernabeu-Mira. Data collection: Luigi Canullo and Fabio Camacho-Alonso. Writing—original draft preparation: Juan Carlos Bernabeu-Mira and Arthur Rodriguez Gonzalez-Cortes. Review and editing: Miguel Peñarrocha-Diago, Luigi Canullo and David Peñarrocha-Oltra. Supervision: Miguel Peñarrocha-Diago. Project administration: David Peñarrocha-Oltra.

ACKNOWLEDGMENT

Mr. Juan Luís Gómez-Martínez for independent and blinded statistical analysis of the data. State Program, Scholarship for University Teacher Training (FPU18/02254) of Juan Carlos Bernabeu-Mira.

FUNDING INFORMATION

The study was not funded by any external source.

CONFLICT OF INTEREST STATEMENT

The authors declare that they have no conflicts of interest related to the study findings and conclusions. There are no financial or other relationships that could influence their objectivity.

DATA AVAILABILITY STATEMENT

The data used in this study are available upon reasonable request. To access the data, please contact to the corresponding author.

ETHICS STATEMENT

This study was conducted in accordance with ethical principles and was approved by the Ethics Committee of the University of Valencia (Valencia, Spain) under approval number 1937615. All participants provided informed consent before participating in the study.

PATIENT CONSENT STATEMENT

All participants in this study provided written informed consent before participating in the research. They were informed about the study objectives, procedures, risks and benefits, and were assured that their participation was voluntary.

PERMISSION TO REPRODUCE MATERIAL FROM OTHER SOURCES

Permission to reproduce material from other sources in this study has been obtained. Details of the permissions are available upon request.

CLINICAL TRIAL REGISTRATION

This clinical trial has been registered with ClinicalTrials.gov under registration number (NCT05286866). Additional information about the trial, including objectives, methods and results, can be found in the respective registry.

ORCID

Juan Carlos Bernabeu-Mira https://orcid.org/0000-0003-1268-5361
Fabio Camacho-Alonso https://orcid.org/0000-0002-3739-1792
Arthur Rodriguez Gonzalez Cortes https://orcid.org/0000-0001-6591-7256
David Peñarrocha-Oltra https://orcid.org/0000-0002-6670-9886

REFERENCES

1. Moraschini V, Poubel LAC, Ferreira VF, Barboza ESP. Evaluation of survival and success rates of dental implants reported in longitudinal studies with a follow-up period of at least 10 years: a systematic review. *Int J Oral Maxillofac Surg*. 2015;44(3):377-388. doi:10.1016/j.ijom.2014.10.023
2. Albrektsson T, Brånemark PI, Hansson HA, Lindström J. Osseointegrated titanium implants. Requirements for ensuring a long-lasting, direct bone-to-implant anchorage in man. *Acta Orthop Scand*. 1981;52(2):155-170. doi:10.3109/17453678108991776
3. Eriksson AR, Albrektsson T. Temperature threshold levels for heat-induced bone tissue injury: a vital-microscopic study in the rabbit. *J Prosthet Dent*. 1983;50(1):101-107. doi:10.1016/0022-3913(83)90174-9
4. Flanagan D. Osteotomy irrigation: is it necessary? *Implant Dent*. 2010;19(3):241-249. doi:10.1097/ID.0b013e3181dc9852
5. Möhlhenrich SC, Modabber A, Steiner T, Mitchell DA, Hölzle F. Heat generation and drill wear during dental implant site preparation: systematic review. *Br J Oral Maxillofac Surg*. 2015;53(8):679-689. doi:10.1016/j.bjoms.2015.05.004
6. Tehemar SH. Factors affecting heat generation during implant site preparation: a review of biologic observations and future considerations. *Int J Oral Maxillofac Implants*. 1999;14(1):127-136.
7. Anitua E, Carda C, Andia I. A novel drilling procedure and subsequent bone autograft preparation: a technical note. *Int J Oral Maxillofac Implants*. 2007;22(1):138-145.
8. Bernabeu-Mira JC, Soto-Peñaloza D, Peñarrocha-Diago M, Camacho-Alonso F, Rivas-Ballester R, Peñarrocha-Oltra D. Low-speed drilling without irrigation versus conventional drilling for dental implant osteotomy preparation: a systematic review. *Clin Oral Investig*. 2021;25(7):4251-4267. doi:10.1007/s00784-021-03939-z
9. Calvo-Guirado JL, Delgado-Peña J, Maté-Sánchez JE, Mareque Bueno J, Delgado-Ruiz RA, Romanos GE. Novel hybrid drilling protocol: evaluation for the implant healing—thermal changes, crestal bone loss, and bone-to-implant contact. *Clin Oral Implants Res*. 2015;26(7):753-760. doi:10.1111/clr.12341
10. de San José LF, Ruggeri FM, Rucco R, et al. Influence of drilling technique on the radiographic, thermographic, and Geomorphometric effects of dental implant drills and osteotomy site preparations. *J Clin Med*. 2020;9(11):3631. doi:10.3390/jcm9113631

17088208, 2024, 4, Downloaded from https://onlinelibrary.wiley.com/doi/10.1111/cdd.13346 by Dr. Juan Carlos Bernabeu-Mira - Universitat De Valencia , Wiley Online Library on [06/10/2025]. See the Terms and Conditions (https://onlinelibrary.wiley.com/terms-and-conditions) on Wiley Online Library for rules of use; OA articles are governed by the applicable Creative Commons License

11. Oh J, Fang Y, Jeong S, Choi B. The effect of low-speed drilling without irrigation on heat generation: an experimental study. *J Korean Assoc Oral Maxillofac Surg*. 2016;42(1):9-12. doi:10.5125/jkaoms.2016.42.1.9
12. Salomó-Coll O, Auriol-Muerza B, Lozano-Carrascal N, Hernández-Alfaro F, Wang H, Gargallo-Albiol J. Influence of bone density, drill diameter, drilling speed, and irrigation on temperature changes during implant osteotomies: an in vitro study. *Clin Oral Investig*. 2021;25(3):1047-1053. doi:10.1007/s00784-020-03398-y
13. Pellicer-Chover H, Peñarrocha-Oltra D, Aloy-Prosper A, Sanchis-Gonzalez J, Peñarrocha-Diago M, Peñarrocha-Diago M. Comparison of peri-implant bone loss between conventional drilling with irrigation versus low-speed drilling without irrigation. *Med Oral Patol Oral Cir Bucal*. 2017;22(6):e730-e736. doi:10.4317/medoral.21694
14. Tabassum A, Kazmi F, Wismeijer D, Siddiqui IA, Tahmaseb A. A prospective randomized clinical trial on radiographic crestal bone loss around dental implants placed using two different drilling protocols: 12-month follow-up. *Int J Oral Maxillofac Implants*. 2021;36(6):e175-e182. doi:10.11607/jomi.9029
15. Liang C, Lin X, Wang S, Guo L, Wang X, Li J. Osteogenic potential of three different autogenous bone particles harvested during implant surgery. *Oral Dis*. 2017;23(8):1099-1108. doi:10.1111/odi.12704
16. Tabassum A, Wismeijer D, Hogervorst J, Tahmaseb A. Comparison of proliferation and differentiation of human osteoblast-like cells harvested during implant osteotomy preparation using two different drilling protocols. *Int J Oral Maxillofac Implants*. 2020;35(1):141-149. doi:10.11607/jomi.7648
17. Coyac BR, Salvi G, Leahy B, et al. A novel system exploits bone debris for implant osseointegration. *J Periodontol*. 2021;92(5):716-726. doi:10.1002/JPER.20-0099
18. Coyac BR, Sun Q, Leahy B, et al. Optimizing autologous bone contribution to implant osseointegration. *J Periodontol*. 2020;91(12):1632-1644. doi:10.1002/JPER.19-0524
19. Miron RJ, Gruber R, Hedbom E, et al. Impact of bone harvesting techniques on cell viability and the release of growth factors of autografts. *Clin Implant Dent Relat Res*. 2013;15(4):481-489. doi:10.1111/j.1708-8208.2012.00440.x
20. Miron RJ, Hedbom E, Saulacic N, et al. Osteogenic potential of autogenous bone grafts harvested with four different surgical techniques. *J Dent Res*. 2011;90(12):1428-1433. doi:10.1177/0022034511422718
21. Benic GI, Hämmerle CH. Horizontal bone augmentation by means of guided bone regeneration. *Periodontol 2000*. 2014;66(1):13-40. doi:10.1111/prd.12039.
22. Retzepi M, Donos N. Guided bone regeneration: biological principle and therapeutic applications. *Clin Oral Implants Res*. 2010;21(6):567-576. doi:10.1111/j.1600-0501.2010.01922.x
23. Buser D, Dula K, Hess D, Hirt HP, Belser UC. Localized ridge augmentation with autografts and barrier membranes. *Periodontology 2000*. 1999;19:151-163. doi:10.1111/j.1600-0757.1999.tb00153.x
24. Hanser T, Khoury F. Extraction site management in the esthetic zone using autogenous hard and soft tissue grafts: a 5-year consecutive clinical study. International journal of periodontics. *Restorative Dent*. 2015;34(3):305-312. doi:10.11607/prd.1749
25. Khoury F, Hanser T. Three-dimensional vertical alveolar ridge augmentation in the posterior maxilla: a 10-year clinical study. *Int J Oral Maxillofac Implants*. 2019;34(2):471-480. doi:10.11607/jomi.6869
26. Verdugo F. Autogenous bone block grafting provides facial implant tissue stability long-term. *Clin Implant Dent Relat Res*. 2017;19(3):478-485. doi:10.1111/cid.1247
27. Lee I, Lim H, Lee J, Hong J, Choi S, Jung U. Layered approach with autogenous bone and bone substitute for ridge augmentation on implant dehiscence defects in dogs. *Clin Oral Implants Res*. 2016;27(5):622-628. doi:10.1111/clr.12649
28. Meloni SM, Jovanovic SA, Urban I, Canullo L, Pisano M, Tallarico M. Horizontal ridge augmentation using GBR with a native collagen membrane and 1:1 ratio of Particulated xenograft and autologous bone: A 1-year prospective clinical study. *Clin Implant Dent Relat Res*. 2017;19(1):38-45. doi:10.1111/cid.12429
29. Urban IA, Nagursky H, Lozada JL, Nagy K. Horizontal ridge augmentation with a collagen membrane and a combination of particulated autogenous bone and anorganic bovine bone-derived mineral: a prospective case series in 25 patients. *Int J Periodontics Restorative Dent*. 2013;33(3):299-307. doi:10.11607/prd.1407
30. Lekholm U, Zarb GA. Patient selection and preparation. In: Brånemark P-I, Zarb GA, Albrektsson T, eds. *Tissue Integrated Prostheses: Osseointegration in Clinical Dentistry*. 1st ed. Quintessence; 1985.
31. Misch CE, Dietsh-Misch F, Hoar J, Beck G, Hazen R, Misch CM. A bone quality-based implant system: first year of prosthetic loading. *J Oral Implantol*. 1999;25(3):185-197. doi:10.1563/1548-1336(1999)025
32. Norton MR, Gamble C. Bone classification: an objective scale of bone density using the computerized tomography scan. *Clin Oral Implants Res*. 2001;12(1):79-84. doi:10.1034/j.1600-0501.2001.012001079.x
33. Cortes AR, Eimar H, Barbosa Jde S, Costa C, Arita ES, Tamimi F. Sensitivity and specificity of radiographic methods for predicting insertion torque of dental implants. *J Periodontol*. 2015;86(5):646-655. doi:10.1902/jop.2015.140584
34. González-García R, Monje F. The reliability of cone-beam computed tomography to assess bone density at dental implant recipient sites: a histomorphometric analysis by micro-CT. *Clin Oral Implants Res*. 2013;24(8):871-879. doi:10.1111/j.1600-0501.2011.02390.x
35. Schulz KF, Altman DG, Moher D, CONSORT Group. CONSORT 2010 statement: updated guidelines for reporting parallel group randomised trials. *PLoS Med*. 2010;7(3):e1000251. doi:10.1371/journal.pmed.1000251
36. Turkyilmaz I, Tumer C, Ozbek EN, Tözüm TF. Relations between the bone density values from computerized tomography, and implant stability parameters: a clinical study of 230 regular platform implants. *J Clin Periodontol*. 2007;34(8):716-722. doi:10.1111/j.1600-051X.2007.01112.x
37. Salimov F, Tatli U, Kürkçü M, Akoğlan M, Oztunç H, Kurtoğlu C. Evaluation of relationship between preoperative bone density values derived from cone beam computed tomography and implant stability parameters: a clinical study. *Clin Oral Implants Res*. 2014;25(9):1016-1021. doi:10.1111/clr.12219
38. Li WT, Li P, Piao MZ, Zhang F, Di J. Study on bone volume harvested from the implant sites with different methods. *Beijing Da Xue Xue Bao Yi Xue Ban*. 2020;52(1):103-106. Chinese. doi:10.19723/j.issn.1671-167X.2020.01.016
39. Verdugo F, Simonian K, D'Addona A, Pontón J, Nowzari H. Human bone repair after mandibular symphysis block harvesting: a clinical and tomographic study. *J Periodontol*. 2010a;81(5):702-709. doi:10.1902/jop.2010.090612
40. Verdugo F, Simonian K, Raffaelli L, D'Addona A. Computer-aided design evaluation of harvestable mandibular bone volume: a clinical and tomographic human study. *Clin Implant Dent Relat Res*. 2014;16(3):348-355. doi:10.1111/cid.12011
41. Verdugo F, Simonian K, Smith McDonald R, Nowzari H. Quantitation of mandibular symphysis volume as a source of bone grafting. *Clin Implant Dent Relat Res*. 2010b;12(2):99-104. doi:10.1111/j.1708-8208.2008.00140.x
42. Verdugo F, Simonian K, Smith McDonald R, Nowzari H. Quantitation of mandibular ramus volume as a source of bone grafting. Clinical implant dentistry related. *Research*. 2009;11 Suppl 1:e32-e37. doi:10.1111/j.1708-8208.2009.00172.x
43. Jung RE, Thoma DS, Hammerle CHF. Assessment of the potential of growth factors for localized alveolar ridge augmentation: a systematic review. *J Clin Periodontol*. 2008;35(8 Suppl):255-281. doi:10.1111/j.1600-051X.2008.01270.x

17088208, 2024, 4, Downloaded from https://onlinelibrary.wiley.com/doi/10.1111/cid.13346 by Dr. Juan Carlos Bernabeu-Mira - Universitat De València , Wiley Online Library on [06/10/2025]. See the Terms and Conditions (https://onlinelibrary.wiley.com/terms-and-conditions) on Wiley Online Library for rules of use; OA articles are governed by the applicable Creative Commons License

44. Anitua E. Biological drilling: implant site preparation in a conservative manner and obtaining autogenous bone grafts. *Balk J Dent Med*. 2018;22:98-101.
45. Starch-Jensen T, Deluiz D, Deb S, Bruun NH, Tinoco EMB. Harvesting of autogenous bone graft from the ascending mandibular ramus compared with the Chin region: a systematic review a4nd meta-analysis focusing on complications and donor site morbidity. *J Oral Maxillofac Res*. 2020;11(3):e1. doi:10.5037/jomr.2020.11301
46. Verdugo F, Laksmana T, D'Addona A, Uribarri A. Facial cortical bone regeneration post-extraction in non-grafted sockets allows for early implant placement and long-term functional stability. *Arch Oral Biol*. 2020;112:104678. doi:10.1016/j.archoralbio.2020.104678

How to cite this article: Bernabeu-Mira JC, Peñarrocha-Diago M, Canullo L, Camacho-Alonso F, Cortes ARG, Peñarrocha-Oltra D. Autologous bone harvested during implant bed preparation: A randomized clinical trial comparing high-speed drilling with irrigation versus low-speed drilling without irrigation. *Clin Implant Dent Relat Res*. 2024; 26(4):724-733. doi:10.1111/cid.13346

17088208, 2024, 4, Downloaded from https://onlinelibrary.wiley.com/doi/10.1111/cid.13346 by Dr. Juan Carlos Bernabeu-Mira - Universitat De Valencia , Wiley Online Library on [06/10/2026]. See the Terms and Conditions (https://onlinelibrary.wiley.com/terms-and-conditions) on Wiley Online Library for rules of use; OA articles are governed by the applicable Creative Commons License