Journal of
Functional Biomaterials

MDPI

Article

Alloplastic Graft vs. Bovine Xenograft in Bone Regeneration: An Experimental Study in Rabbits

Eugenio Velasco-Ortega [1,*], Marta Díaz-Pérez [1], Francisco Monje Valladolid [1], Fernando Muñoz-Guzón [2,*], Loreto Monsalve-Guil [1], Iván Ortiz-Garcia [1], Enrique Núñez-Márquez [1], Jesús Moreno-Muñoz [1], Jose Luis Rondón-Romero [1] and Álvaro Jiménez-Guerra [1]

[1] Department of Stomatology, Faculty of Dentistry, University of Seville, 41009 Seville, Spain; jolurr001@us.es (J.L.R.-R.)
[2] Ibonelab SL, Department of Veterinary Clinical Sciences, Faculty of Veterinary, Terra Campus, Universidade de Santiago de Compostela, 27002 Lugo, Spain
* Correspondence: evelasco@us.es (E.V.-O.); fernandom.munoz@usc.es (F.M.-G.)

Abstract

This study aimed to compare bone regeneration following the application of deproteinized bovine bone mineral (DBBM) and β-tricalcium phosphate (β-TCP) in experimentally created rabbit tibial defects using micro-computed tomography (micro-CT) and histomorphometric analysis. Eight New Zealand White rabbits were included, with three monocortical defects (3 mm in diameter) created in each tibia. The defects were randomly allocated to an unfilled control group, a DBBM group, or a β-TCP group. Bone regeneration was evaluated 12 weeks after surgery. Micro-CT analysis showed mean bone volume fractions (BV/TV) of 56.90 ± 17.50%, 64.57 ± 16.85%, and 71.78 ± 14.59% in the control, DBBM, and β-TCP groups, respectively. However, pairwise differences were not statistically significant after Bonferroni adjustment. Histomorphometric analysis also showed the highest mean percentage of newly formed bone in the β-TCP group (54.99 ± 11.42%), followed by DBBM (46.80 ± 11.44%) and the control group (40.14 ± 15.32%). The difference between β-TCP and DBBM did not remain statistically significant after adjustment for multiple comparisons. Both graft materials were associated with bone formation, although spontaneous healing was also observed in untreated defects. β-TCP showed numerically higher bone formation values, but its superiority over DBBM could not be statistically established in this experimental model.

Keywords: β-tricalcium phosphate; deproteinized bovine bone mineral; bone regeneration; rabbit model

Check for updates

Academic Editor: Gustavo Fernandes

Received: 24 October 2026
Revised: 16 November 2026
Accepted: 18 November 2026
Published: 20 November 2026

Copyright: © 2026 by the authors. Licensee MDPI, Basel, Switzerland. This article is an open access article distributed under the terms and conditions of the Creative Commons Attribution (CC BY) license.

1. Introduction

During dental implant treatment, it is sometimes necessary to increase the available bone volume to successfully perform implant placement surgery. In these clinical situations, the use of bone grafts or bone substitutes can achieve healing and regeneration of the alveolar bone defect area. In this regard, in recent decades, new biomaterials have been introduced that have met the clinical expectations of both patients and professionals with very positive results [1–3].

Bone graft materials can be of different origins; autografts, allografts, xenografts, and alloplastic materials are the most commonly used in implant dentistry. The need for an additional surgical site, the limited availability of autografts, and the surgeon's skill level have reduced the use of autologous bone. The risk associated with the transmission of

infectious diseases has been a significant drawback for allografts derived from cadaver bone. These disadvantages have driven the need to develop alternative bone substitutes [4–6].

Bone substitutes of animal origin such as deproteinized bovine bone mineral (DBBM) offer some advantages, as they acquire biological and mechanical characteristics comparable to human bone. However, xenografts may contain non-human proteins and carry potential infectious diseases, therefore requiring deproteinization and sterilization to be used safely in human applications. These drawbacks are avoided by the introduction of synthetic materials such as β-tricalcium phosphate (β-TCP), which have proven to be a successful alternative in the treatment of bone defects [7,8].

From a clinical perspective, the application of bone substitutes in implant practice constitutes a treatment option with a high degree of predictability. However, the graft must have suitable characteristics to achieve three-dimensional stability with respect to the type of defect. The characteristics of bone graft substitutes must include biological properties of biocompatibility and osteoconductive capacity that promote the formation of new bone and allow for the regeneration of the bone defect. In this regard, aspects related to the physical and chemical structure of the bone substitute are also important, such as granule size, porosity, hydrophilicity, and the degradation process [9–12].

DBBM is widely used in clinical practice, primarily due to its safety and slow degradation, reflecting its persistence and histological integration into the host bone. DBBM has been used successfully in various surgical implant placement techniques. In maxillary sinus lifts, DBBM has been used alone or in combination with other bone grafts or substitutes. DBBM has demonstrated good space maintenance capabilities, although it exhibited varying levels of residual particles and less integration [7,13].

Alloplastic biomaterials have gained popularity in recent years, primarily due to their advantages such as their constant availability and minimal risk of disease transmission. Among alloplastic materials, the most widely used is β-TCP, which adheres to the surrounding bone, has osteoconductive properties, and is completely resorbed over time. β-TCP has shown promising results in bone regeneration studies in oral implantology [14–16].

Experimental and clinical research are frequent in the field of bone substitutes for implant dentistry. In this regard, preclinical studies in experimental animals allow for the histological evaluation of bone healing and regeneration processes after the use of bone grafts or substitutes. Rabbit models are chosen due to their anatomical and physiological similarities to bone healing processes in humans. Furthermore, rabbits provide sufficient blood volume for faster bone remodeling compared to other animal models in implant dentistry [17–22]. The objective of this study was to evaluate and compare, through micro-CT and histological analysis, the bone regeneration capacity of two different biomaterials, DBBM and β-TCP, in experimentally created bone defects in New Zealand rabbit tibias.

2. Materials and Methods

2.1. Animals

Eight healthy adult New Zealand White rabbits (Granja San Bernardo, Navarra, Spain) aged 6–7 months and weighing approximately 5 kg were included in the study. Both tibias of each animal were surgically treated, providing a total of 16 experimental tibias. Three monocortical bone defects, 3 mm in diameter, were created in each tibia and allocated to one of three experimental conditions: an unfilled control, deproteinized bovine bone mineral (DBBM), or β-tricalcium phosphate (β-TCP).

The sample size was determined based on experimental and ethical considerations, with the aim of minimizing the number of animals used in accordance with the reduction principle of the 3Rs. No formal a priori sample size calculation was performed.

Thus, a total of 48 bone defects were initially created, corresponding to 16 defects per experimental group. Some specimens could not be included in the final analysis because of technical difficulties encountered during the experimental procedures. Consequently, the number of evaluable specimens varied according to the analytical method and outcome assessed. The reason for exclusion and the final sample sizes are reported in the corresponding sections.

The experimental protocol was approved by the Ethics Committee of the University of Córdoba (approval reference: 2022PI/40; approval date: 20 December 2022). All procedures were conducted at the Animal Experimentation Facility of the University of Córdoba, Spain, in accordance with Spanish and European regulations on the care and use of animals for scientific purposes. Animals were housed in enriched rabbit cages that allowed normal activity and were monitored daily by trained personnel to assess their general health. Food and tap water were provided ad libitum.

2.2. Bone Substitutes

Three monocortical bone defects (3 mm in diameter) were created in each tibia. The allocation of the three experimental conditions (control, DBBM, and β-TCP) to the defect positions was randomized, so that no experimental condition was systematically assigned to a proximal or distal location.

Group I (Control group): The defect remained unfilled.

Group II (DBBM): The bone defect was filled with deproteinized bovine bone mineral (TechbiomatBone®, Techbiomat, Barcelona, Spain), a xenogeneic bone substitute of bovine origin composed predominantly of hydroxyapatite. The particle size ranged from 0.25 to 1.68 mm, with a reported porosity of approximately 61%, an internal surface area of 78.5 m^2/g, and a Ca/P ratio of 1.68–1.71. X-ray diffraction analysis reported in the product documentation identified a crystalline hydroxyapatite phase.

Group III (β-TCP): The bone defect was filled with a synthetic alloplastic bone substitute composed of β-tricalcium phosphate (Osteoblast®, Galimplant, Sarria, Spain). According to the manufacturer's specifications, the particle size ranged from 0.25 to 1.00 mm.

The physicochemical characteristics reported above were obtained from available manufacturer documentation and previously published technical data. No independent physicochemical characterization of the biomaterial batches used in this study was performed.

2.3. Surgical Procedures

All surgical procedures were performed in an operating room under sterile conditions, and under general anesthesia induced and maintained at a concentration of 2.5–4% isoflurane (Isoba-vet®, Schering-Plough, Madrid, Spain) using a facemask. The animals were first sedated with a combination of medetomidine (0.05 mg/kg/i.m., Domtor®, Esteve, Barcelona, Spain) and ketamine (25 mg/kg/i.m., Imalgène 1000®, Merial, Toulouse, France). During anesthesia, the animals were continuously monitored by a veterinarian category B or C.

The animals received antibiotic prophylaxis for one week with enrofloxacin (15 mg/Kg/s.c. once a day, Ganadexil 5%®, Invesa, Barcelona, Spain) and pain was controlled with meloxicam (0.2 mg/Kg/s.c., Metacam®, Boehringer Ingelheim, Barcelona, Spain) during three days. The animals were monitored daily throughout the postoperative period for signs of pain, discomfort, or other complications. Veterinary intervention was provided if signs of distress or deterioration in general health were detected, and early humane euthanasia was considered when necessary to prevent unnecessary suffering.

After a three-week quarantine period, the animals underwent general anesthesia. After shaving and disinfecting, the tibia was exposed by a medial longitudinal incision. Bone defects were created according to the manufacturers' recommendations. Finally, the muscle, the subcutaneous tissue, and the skin were sutured in layers with reabsorbable sutures (Vicryl 4-0®, Ethicon, Raritan, NJ, USA).

Twelve weeks after surgery, the rabbits were humanely euthanized by a sodium pentobarbital overdose (100 mg/Kg/i.v., Dolethal®, Vétoquinol, Madrid, Spain) after sedation with ketamine and medetomidine.

2.4. µCT Analysis

All samples were scanned using a high-resolution microCT scanner (Skyscan 1172, Bruker microCT NV®, Kontich, Belgium). The X-ray source was set to 79 kV and 125 µA with a pixel size of 9.98 µm, and a 0.5 mm aluminum (Al 0.5) filter was used. The scanner was rotated 360°, and images were acquired every 0.4°. All samples were scanned using the same parameters.

The images were then reconstructed using NRecon software® V.1.7.4.6.(Bruker microCT NV, Kontich, Belgium) based on the Feldkamp algorithm. The same reconstruction parameters were used for all samples (to allow comparison). Using Data Viewer software, we oriented the tibias perpendicular to the X axis, selected the VOI (region of interest, in this case, the defect), and saved the sagittal view for analysis in each of the three defects in all samples.

The CTAn software® V.1.7.4.6 (Bruker microCT NV®, Kontich, Belgium) was used for sample analysis. The sagittal view was opened in CTAn, and a VOI was manually selected following a common criterion for all defects and samples (encompassing as much biomaterial as possible). A second VOI selection was then performed, this time using a 3 mm circular VOI (similar to the cylinder used).

The threshold for the samples was manually selected using the CTAn software (Figure 1). The threshold values for selecting bone were set at 50–255, and for biomaterial, they were set at 120–255. These thresholds were selected for the 3 mm circular VOI and the manually selected VOI for all defects and all samples. Note: In defects that do not contain biomaterial, only the values for bone are selected, and therefore only this is analyzed. The grayscale thresholds were manually defined and applied consistently across all samples. All micro-CT analyses were performed using coded samples, with the examiner blinded to the experimental group allocation. Because the threshold ranges used for bone and residual biomaterial overlapped, some voxels may have been included in both measurements. This potential limitation was considered when interpreting the micro-CT results.

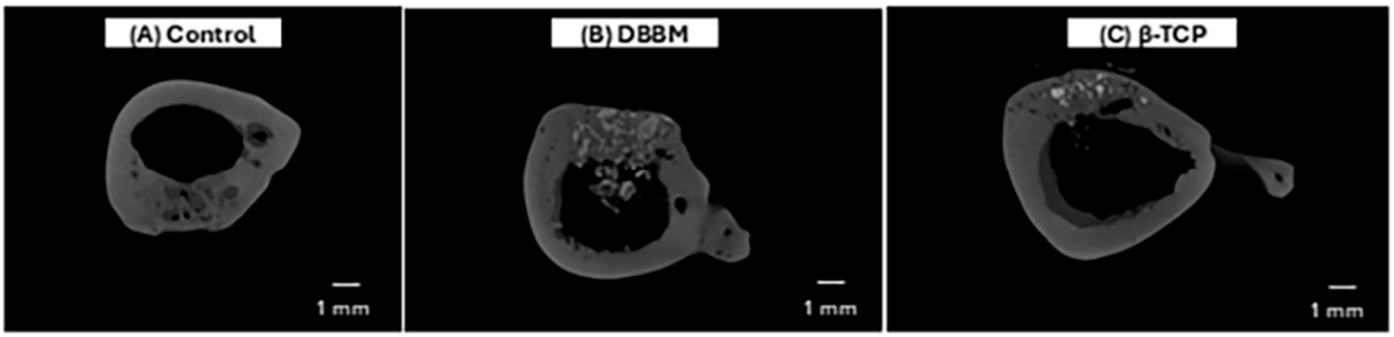

Figure 1. Representative micro-computed tomography (micro-CT) images of rabbit tibial bone defects 12 weeks after surgery. (**A**) Control group (unfilled defect); (**B**) deproteinized bovine bone mineral (DBBM) group; and (**C**) β-tricalcium phosphate (β-TCP) group.

Finally, the samples were analyzed, and the percentage of bone (BV/TV) and biomaterial was calculated in the volume of interest, which allows us to know the proportion of its volume with respect to the total volume of tissue examined.

A total of 16 specimens per experimental group were initially available for micro-CT evaluation. However, some specimens could not be included in the final analysis because of technical difficulties encountered during sample preparation and processing. Consequently, the number of evaluable specimens varied among groups and according to the parameter assessed. The final sample size for each parameter is reported in the corresponding results.

2.5. Histological and Histomorphometric Analyses

The blocks containing the preparations were obtained using an oscillating saw, fixed and identified. These blocks were dehydrated in different graded ethanol series and infiltrated with different graded mixtures of ethanol and glycometacrylate (Technovit 7200 VLC®, Heraus Kulzer, Wehrheim, Germany). The samples were then polymerized and heated at 37 °C for 24 h to ensure complete polymerization.

Each block was radiographed to determine the center of each preparation. Longitudinal sections (central sections) were prepared using a band saw and mechanically micropolished (Exakt Apparatebau®, Norderstedt, Germany) using 1200 and 4000 grit silicon carbide papers (Struers®, Copenhagen, Denmark) until sections approximately 40 µm thick were obtained [23]. The slides were stained using the Levai-Laczkó method [24] for both histological and histomorphometric analysis.

Following histological preparation, images were captured using an optical microscope (BX51, Olympus, Tokyo, Japan) connected to a digital color camera (DP71, Olympus, Tokyo, Japan) with a motorized plate (Märzhäuser, Steindorf, Germany). The images obtained were automatically aligned and stitched together, producing complete images of the bone and the bone substitute (Figure 2).

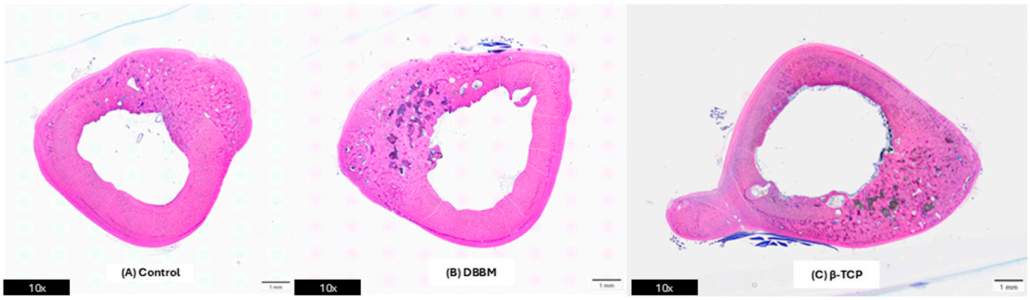

Figure 2. Histological images of rabbit tibial bone defects 12 weeks after surgery. Sections were stained using the Levai–Laczkó method. (**A**) Control group (unfilled defect); (**B**) deproteinized bovine bone mineral (DBBM) group; and (**C**) β-tricalcium phosphate (β-TCP) group.

The digital images were painted using the Photoshop software 26.11(Adobe, San Jose, CA, USA) (Figure 3) by a masked examiner. Subsequently, a Region of Interest (ROI) was established for each defect in each sample, represented in image analysis software Cell-sens, Imaging software 4.3.1. (Olympus Corporation, Tokyo, Japan). The ROI established for the defects is a cylinder with an area of 8 mm^2 (approximately 3 mm in diameter) that simulates the size of the cylinder inserted into the bone. Furthermore, it is located approximately in the area where the insertion occurred, based on the condition of the bone, biomaterial (if applicable), and microCT analysis. The percentages of bone and biomaterial in the region of interest were automatically obtained from the software (Figure 3).

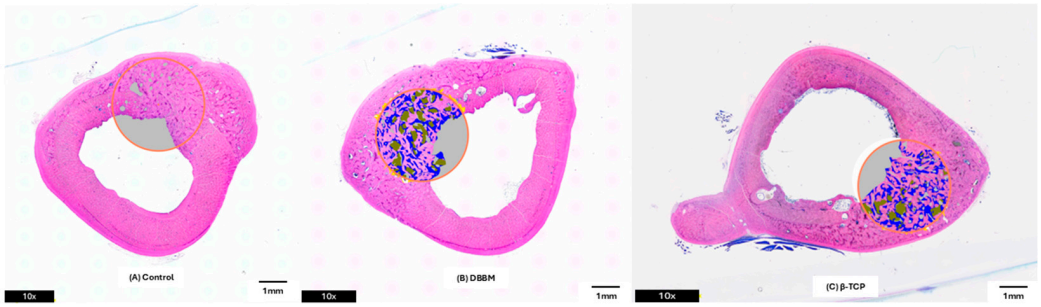

Figure 3. Representative histological images of rabbit tibial bone defects 12 weeks after surgery, digitally processed to identify the regions of interest (ROIs) used for histomorphometric analysis. (**A**) Control group (unfilled defect); (**B**) deproteinized bovine bone mineral (DBBM) group; and (**C**) β-tricalcium phosphate (β-TCP) group.

Of the 16 specimens initially available per experimental group, 12 were successfully processed and included in the final histological and histomorphometric analyses. The remaining specimens were excluded because of technical difficulties encountered during sample preparation and histological processing. These exclusions were unrelated to the experimental treatments.

2.6. Statistical Analysis

Statistical analyses were performed using IBM SPSS Statistics, version 25.0 (IBM Corp., Armonk, NY, USA). Quantitative data are presented as means and standard deviations. Normality was assessed using the Kolmogorov–Smirnov test. Repeated-measures analysis of variance (ANOVA) was used to assess differences among the three experimental conditions (control, DBBM, and β-TCP). Pairwise comparisons were performed using paired-samples Student's *t*-tests, with Bonferroni adjustment for the three comparisons among experimental groups. For comparisons involving only DBBM and β-TCP, paired-samples t-tests were used. Statistical significance was set at $p < 0.05$.

3. Results

In all New Zealand White rabbits, the treated areas healed well after surgery. Periodic examinations during the first few weeks post-surgery confirmed the absence of infection or inflammation. Both biomaterials showed evidence of integration with the surrounding bone after the 12-week period and were available for histological analysis. In all 3 groups, a process of bone healing and regeneration was observed in the living bone tissue.

3.1. µCT Analysis

Micro-CT analysis using a standardized circular volume of interest (VOI) showed a mean bone volume fraction (BV/TV) of 56.90 ± 17.50% in the control group ($n = 13$), 64.57 ± 16.85% in the DBBM group ($n = 14$), and 71.78 ± 14.59% in the β-TCP group ($n = 13$) (Table 1). The highest mean BV/TV was observed in the β-TCP group, followed by DBBM and the control group. Pairwise comparisons of BV/TV using the standardized circular VOI showed no statistically significant differences between the control and DBBM groups ($p = 0.092$), the control and β-TCP groups ($p = 0.063$), or the DBBM and β-TCP groups ($p = 0.088$). These differences remained non-significant after Bonferroni adjustment (adjusted $p = 0.276$, 0.189, and 0.264, respectively).

Table 1. µCT analysis. Bone Volume/Tissue Volume ratio (BV/TV). Values are expressed as percentages. DBBM: deproteinized bovine bone mineral; β-TCP: beta-tricalcium phosphate; SD: standard deviation. Dashes indicate unavailable measurements due to technical difficulties during sample preparation and processing. The number of evaluable specimens was 13 for the control group, 14 for DBBM, and 13 for β-TCP.

Samples	Control (%)	DBBM (%)	β-TCP (%)
0725_1.1	-	77.513	-
0725_1B.1	24.951	81.718	66.132
0725_2B.1	38.936	27.719	58.571
0725_3.1	40.780	54.950	39.604
0725_3B.1	44.161	58.654	76.571
0725_4B.2	45.204	78.329	94.846
0725_5.1	46.145	44.841	51.028
0725_5B.1	65.156	78.862	77.503
0725_7.1	65.912	81.675	80.269
0725_8.1	67.298	62.612	73.183
0725_9.1	71.121	68.120	77.733
0725_10.1	74.290	55.852	79.542
0725_11.1	75.196	49.658	82.031
0725_12.1	80.561	83.408	76.176
n	13	14	13
Mean (%)	56.90	64.57	71.78
SD (%)	17.50	16.85	14.59

The residual biomaterial volume fraction (Biomat/TV), assessed using the standardized circular VOI, was 6.90 ± 3.51% in the DBBM group ($n = 14$) and 5.44 ± 4.82% in the β-TCP group ($n = 12$) (Table 2). The mean residual biomaterial fraction was numerically lower in the β-TCP group. The difference in residual biomaterial volume fraction between DBBM and β-TCP was not statistically significant ($p = 0.308$; 95% CI for the paired difference: −1.35 to 3.90 percentage points).

Table 2. µCT analysis: Residual biomaterial volume fraction (Biomat/TV, %) assessed by micro-CT using a standardized circular volume of interest (VOI). Values are expressed as percentages. DBBM: deproteinized bovine bone mineral; β-TCP: beta-tricalcium phosphate; SD: standard deviation. Dashes indicate unavailable measurements due to technical difficulties during sample preparation and processing. The number of evaluable specimens was 14 for DBBM and 12 for β-TCP.

Samples	DBBM (%)	β-TCP (%)
0725_1.1	11.809	-
0725_1B.1	4.300	-
0725_2B.1	11.887	4.334
0725_3.1	8.047	16.672
0725_3B.1	1.124	0.467
0725_4B.2	0.486	0.318
0725_5.1	8.108	11.849
0725_5B.1	4.422	1.541
0725_7.1	8.208	6.456
0725_8.1	8.684	3.785
0725_9.1	6.995	5.763
0725_10.1	5.228	2.256
0725_11.1	10.550	7.659
0725_12.1	6.813	4.167
n	14	12
Mean (%)	6.90	5.44
SD (%)	3.51	4.82

3.2. Histology and Histomorphometry

Histomorphometric analysis showed a mean newly formed bone area of 3.23 ± 1.23 mm^2 in the control group, 3.77 ± 0.92 mm^2 in the DBBM group, and 4.42 ± 0.92 mm^2 in the β-TCP group. The corresponding percentages of newly formed bone were 40.14 ± 15.32%, 46.80 ± 11.44%, and 54.99 ± 11.42%, respectively (Table 3). The highest mean values were observed in the β-TCP group. The β-TCP group showed higher mean values of newly formed bone area and percentage than the DBBM group. The unadjusted paired comparisons yielded $p = 0.033$ for bone area and $p = 0.032$ for bone percentage. However, these differences did not remain statistically significant after Bonferroni adjustment for three pairwise comparisons (adjusted $p = 0.099$ and $p = 0.096$, respectively).

Table 3. Percentage of newly formed bone determined by histomorphometric analysis. Values are expressed as percentages. Control: defects without biomaterial; DBBM: deproteinized bovine bone mineral; β-TCP: beta-tricalcium phosphate; SD: standard deviation. Twelve specimens were evaluated in each group.

Samples	Control (%)	DBBM (%)	β-TCP (%)
0725_1B.1	29.63	46.83	56.43
0725_3.1	20.27	35.51	47.26
0725_3B.1	23.30	33.05	58.98
0725_4B.2	30.87	57.43	72.74
0725_5.1	38.73	42.44	40.17
0725_5B.1	72.49	60	66.17
0725_7.1	56.60	67.82	69.01
0725_8.1	49.47	44.91	53.57
0725_9.1	33.98	33.98	52.24
0725_10.1	29.13	50.19	60.39
0725_11.1	48.84	35.02	48.39
0725_12.1	48.32	54.4	34.52
n	12	12	12
Mean (%)	40.14	46.80	54.99
SD (%)	15.32	11.44	11.42

Histomorphometric analysis showed a mean soft tissue area of 4.82 ± 1.23 mm^2 in the control group, 3.22 ± 1.13 mm^2 in the DBBM group, and 2.90 ± 0.68 mm^2 in the β-TCP group. The corresponding soft tissue percentages were 59.86 ± 15.32%, 40.06 ± 14.09%, and 35.99 ± 8.51%, respectively (Table 4). The control group showed the highest mean soft tissue percentage, whereas the lowest mean value was observed in the β-TCP group.

Table 4. Percentage of soft tissue determined by histomorphometric analysis. Values are expressed as percentages. Control: defects without biomaterial; DBBM: deproteinized bovine bone mineral; β-TCP: beta-tricalcium phosphate; SD: standard deviation. Twelve specimens were evaluated in each group.

Samples	Control (%)	DBBM (%)	β-TCP (%)
0725_1B.1	70.37	44.55	36.95
0725_3.1	79.73	29.43	33.55
0725_3B.1	76.70	59.23	32.14
0725_4B.2	69.13	29.13	25.8
0725_5.1	61.27	56.82	39.1
0725_5B.1	27.51	26.99	25.91
0725_7.1	43,40	19.07	29.18
0725_8.1	50.53	39.75	39.75
0725_9.1	66.02	64.36	38.57

Table 4. *Cont.*

Samples	Control (%)	DBBM (%)	β-TCP (%)
0725_10.1	70.87	38.71	30.91
0725_11.1	51.16	41.39	43.87
0725_12.1	51.68	31.27	56.09
n	12	12	12
Mean (%)	59.86	40.06	35.99
SD (%)	15.32	14.09	8.51

Histomorphometric analysis showed a mean residual biomaterial area of 1.06 ± 0.74 mm^2 in the DBBM group and 0.73 ± 0.46 mm^2 in the β-TCP group. The corresponding residual biomaterial percentages were 13.14 ± 9.22% and 9.03 ± 5.75%, respectively (Table 5). Paired-samples comparisons showed no statistically significant differences between DBBM and β-TCP in residual biomaterial area ($p = 0.196$) or percentage ($p = 0.193$).

Table 5. Percentage of residual biomaterial determined by histomorphometric analysis. Values are expressed as percentages. DBBM: deproteinized bovine bone mineral; β-TCP: beta-tricalcium phosphate; SD: standard deviation. Twelve specimens were evaluated in each group.

Samples	DBBM (%)	β-TCP (%)
0725_1B.1	8.62	6.62
0725_3.1	35.06	19.19
0725_3B.1	7.72	8.88
0725_4B.2	13.44	1.46
0725_5.1	0.74	20.73
0725_5B.1	13.01	7.92
0725_7.1	13.11	1.81
0725_8.1	15.34	6.68
0725_9.1	1.66	9.19
0725_10.1	11.1	8.7
0725_11.1	23.59	7.74
0725_12.1	14.33	9.39
n	12	12
Mean (%)	13.14	9.03
SD (%)	9.22	5.75

4. Discussion

This study, conducted in experimental animals, evaluates the in vivo response to the placement of biomaterials in New Zealand White rabbits, compared to spontaneous healing without biomaterials. Bone healing and regeneration with the biomaterials used in this study were evaluated through μCT and histological analysis, demonstrating a good response in the host bone without inflammation or infection.

Human bone is a multifunctional organ system that provides structural support, protection, facilitates movement, hematopoiesis, and mineral storage. Bone tissue possesses intrinsic self-repair and remodeling capabilities, generally limited to defects below a critical size. In more complex pathological conditions, such as extensive bone defects, the natural regenerative capacity of bone is often insufficient [25].

This limitation drives the need for advances and research in bone regeneration strategies. In this context, research has been conducted with the aim of developing advanced materials and techniques to stimulate bone healing and regeneration. Bone regeneration involves a sophisticated biological program that requires coordinated biochemical and cellular interaction. The use of biomaterials plays a fundamental role in oral implantology,

mimicking the way the body aids bone regeneration. In this regard, researchers create bone substitutes that function as the extracellular matrix to aid the growth and differentiation of bone cells, facilitating the regeneration of bone defects [26].

In this study, New Zealand White rabbits, which have been used in various histological studies, were used as experimental animals. Surgical protocols for experimentation in these animals frequently involve localized surgery on the tibia, femur, maxilla, or skull, and the placement of various bone substitutes to assess both the phases of bone healing and, subsequently, the replacement of the biomaterial by the formation of new bone characteristic of bone regeneration [19,22,27–32].

Several studies with bone substitutes have been conducted in the jaws of New Zealand White rabbits [27,28,31,32]. A recent study compared the regenerative effect of autogenous microdentin and nanodentin particles on bone regeneration in mandibular defects in rabbits. Nanodentin significantly improved bone density and defect closure, as evidenced by CBCT and histological analysis. Histomorphometric analysis confirmed its superior osteogenic potential, demonstrating greater bone regeneration and graft resorption. These findings highlight nanodentin as a highly effective biomaterial for mandibular bone repair [27]. Other studies have investigated bone regeneration in different anatomical sites in rabbits. Yaşar et al. [19] compared titanium-platelet-rich fibrin (T-PRF) and leukocyte-platelet-rich fibrin (L-PRF) in calvarial defects, reporting improved bone healing compared with untreated controls, particularly in the L-PRF group. Their study also supports the combined use of micro-CT and histological analysis to evaluate bone repair. Fujioka-Kobayashi et al. [22] investigated combinations of deproteinized bovine bone mineral (DBBM) and α-tricalcium phosphate (α-TCP) in rabbit calvarial defects. Although the experimental conditions and materials differed from those of the present study, this investigation is particularly relevant because it evaluated a bovine-derived bone substitute in combination with a calcium phosphate biomaterial. Cetin Genc et al. [32] assessed nanohydroxyapatite-containing scaffolds in rabbit mandibular defects, providing further evidence of the use of rabbit models for evaluating bone regeneration with different biomaterials. Unlike these studies, the present investigation directly compared DBBM and β-TCP in standardized tibial defects, using micro-CT and histomorphometric analyses to assess bone healing and biomaterial remodeling.

In clinical studies evaluating bone healing and regeneration, obtaining homogeneous patient groups is challenging due to individual differences (genetic factors, smoking, alcohol consumption, diet, etc.) and systemic conditions. Therefore, animal models are essential for investigating the pathogenesis of bone healing and repair and evaluating new treatments with biomaterials or bone substitutes [33].

The selection of an appropriate animal model is essential in experimental studies of bone regeneration. Critical-sized defects (CSDs) were originally defined by Schmitz and Hollinger as the smallest bone defects that do not heal spontaneously during the animal's lifetime [34]. However, the dimensions required to produce a critical-sized defect vary according to the animal species, anatomical location, defect geometry, and observation time [35]. New Zealand White rabbits are frequently used in bone regeneration research because of their manageable size, relatively rapid bone remodeling, and suitability for standardized surgical procedures. In the present study, the tibia was selected because it allowed the creation of several standardized defects within the same animal, thereby reducing the number of animals required. The 3-mm diameter was chosen to permit the assessment of bone formation and biomaterial remodeling under reproducible experimental conditions. These defects were not intended to represent critical-sized defects, as spontaneous healing was expected and was confirmed in the untreated control group. Consequently, the findings

should be interpreted as a comparison of bone healing responses rather than evidence of regeneration in defects unable to heal spontaneously.

In the present research study, a good bone response in healing and bone regeneration with partial formation of new bone has been demonstrated. Both in sites without biomaterial, with spontaneous healing, and in sites using DBBM and/or β-TCP, the biological processes of bone regeneration showed favorable progress, although with differential parameters in bone volume and the presence of soft tissue. The results of this research study on bone regeneration in locations without biomaterials and locations using DBBM and/or β-TCP were obtained through the use of a micro-CT study and a histological and histomorphometric analysis.

The anatomical location of the defect is another important consideration when selecting an experimental model. Rabbit calvarial and tibial defects differ in their bone structure and healing characteristics. The calvaria is a flat bone composed of cortical layers surrounding a relatively thin diploic region, whereas the tibia is a long bone with a cortical shaft and an intramedullary cavity. These anatomical differences may influence vascular supply, mechanical loading, and the pattern of bone healing. Calvarial defects are commonly used to assess bone regeneration in a relatively low-load environment, while tibial defects allow the evaluation of biomaterials in a long-bone setting. In the present study, the tibial model also permitted the creation of multiple standardized defects within the same animal, facilitating direct comparisons between treatments while reducing the number of animals required.

Micro-CT provides a three-dimensional assessment of bone structure and is particularly useful for evaluating bone regeneration within experimental defects. In the present study, analysis using a standardized circular volume of interest (VOI) showed mean BV/TV values of 56.90 ± 17.50% in the control group, 64.57 ± 16.85% in the DBBM group, and 71.78 ± 14.59% in the β-TCP group. These findings indicate substantial bone formation after 12 weeks in all three groups, including defects that healed spontaneously without biomaterial. Although the highest mean BV/TV was observed in the β-TCP group, followed by DBBM, the differences between experimental groups were not statistically significant after Bonferroni adjustment for multiple comparisons. The relatively high BV/TV observed in untreated defects also highlights the intrinsic healing capacity of the rabbit tibial model.

The use of micro-CT in the analysis of regenerative bone changes is evaluated in a recent study that aimed to assess the bone healing response of two synthetic bone graft materials in the femur of rabbits. Both materials formed new bone after 4 weeks, present both on the surface and in the spaces between the granules [18]. Micro-CT showed no evidence of infection or adverse reactions at any of the sites. The morphology of the granules was visible on the scans. After 4 weeks, evidence of trabecular bone was observed between the granules and at the host margins in both materials, and the host bone at the edge of the defect appeared to be well integrated with the granules in both materials at 8 weeks. Comparing the results of each material at different time points, significant remodeling of the granules in the filled defects was observed at 12 and 26 weeks [18].

The results of this study showed a relatively low percentage of residual biomaterial at 12 weeks, as assessed by micro-CT using a standardized circular volume of interest (VOI). The mean residual biomaterial fraction was 6.90 ± 3.51% in the DBBM group and 5.44 ± 4.82% in the β-TCP group. Although the mean percentage was lower in the β-TCP group, no statistically significant difference in residual biomaterial fraction was established between the two materials. Furthermore, these findings do not allow conclusions regarding their relative resorption rates.

Histological studies performed in New Zealand White rabbits have shown that spontaneous bone healing progresses through different stages. At two weeks, the defects are partially covered by immature, newly formed bone trabeculae, with small areas of maturing

bone matrix adjacent to the pre-existing defect walls. After four weeks, new bone formation extends throughout the defect, although immature trabeculae remain predominant. By six weeks, maturing bone matrix becomes more prominent, accompanied by larger medullary spaces, primary osteons, and irregularly arranged osteocytes [17].

Histological and histomorphometric analyses confirmed the presence of newly formed bone in all three experimental groups after 12 weeks. The mean percentage of newly formed bone was 40.14 ± 15.32% in the control group, 46.80 ± 11.44% in the DBBM group, and 54.99 ± 11.42% in the β-TCP group. The corresponding soft tissue percentages were 59.86 ± 15.32%, 40.06 ± 14.09%, and 35.99 ± 8.51%, respectively. Residual biomaterial accounted for 13.14 ± 9.22% of the analyzed area in the DBBM group and 9.03 ± 5.75% in the β-TCP group.

These findings indicate that bone formation occurred in both grafted and ungrafted defects, with the highest mean proportion of newly formed bone observed in the β-TCP group. Nevertheless, the persistence of soft tissue and residual biomaterial within the defects indicates that complete replacement by newly formed bone had not occurred at the 12-week evaluation. The histomorphometric findings therefore suggest ongoing tissue remodeling, although the single observation time point does not allow the progression of this process to be determined.

When comparing the two graft materials, the β-TCP group showed higher mean values for both the area and percentage of newly formed bone than the DBBM group. These differences reached statistical significance in the unadjusted paired comparisons ($p = 0.033$ and $p = 0.032$, respectively). However, these differences did not remain statistically significant after Bonferroni adjustment for multiple comparisons (adjusted $p = 0.099$ and $p = 0.096$, respectively).

The regenerative potential of DBBM has been investigated in experimental rabbit models. Previous studies have shown that the physicochemical characteristics of bovine-derived graft materials, including their processing methods, can influence biocompatibility, bone formation, and biomaterial resorption. In a rabbit cranial defect model, a low-temperature processed DBBM xenograft showed favorable tissue integration, without evidence of inflammatory infiltration, necrosis, or connective tissue encapsulation, and promoted newly formed bone compared with untreated defects [20]. In the present study, DBBM was also associated with substantial bone formation after 12 weeks, although the mean values were lower than those observed with β-TCP. The persistence of residual DBBM particles is consistent with the relatively slow remodeling commonly associated with this type of xenograft. However, the present experimental design does not allow its resorption rate to be determined directly.

β-TCP has been widely investigated as a synthetic bone substitute because of its biocompatibility, osteoconductive properties, and ability to undergo gradual resorption during bone remodeling [15,36]. Its porous structure provides a scaffold for bone ingrowth, while its degradation releases calcium and phosphate ions that may contribute to the mineralization process. Previous experimental studies in rabbits have reported favorable bone healing responses following the application of β-TCP in osseous defects [36]. In the present study, β-TCP showed the highest mean values of newly formed bone in both micro-CT and histomorphometric analyses after 12 weeks. Histomorphometry also revealed a lower mean proportion of residual biomaterial in the β-TCP group than in the DBBM group. These findings are consistent with the potential of β-TCP to support bone regeneration, although the differences between materials should be interpreted cautiously in view of the study design and the limitations of the statistical analysis.

Several limitations of this study should be acknowledged. First, the relatively small number of animals limits the statistical power and generalizability of the findings. Although multiple defects were evaluated, observations obtained from the same animal cannot be considered fully independent, and this should be taken into account when interpreting the statistical comparisons. Second, bone regeneration was assessed at a single time point (12 weeks), preventing evaluation of the progression of bone formation and biomaterial resorption over time. Third, the use of small, non-critical-sized defects in the rabbit tibia, which have an inherent capacity for spontaneous healing, may limit the ability to demonstrate the additional regenerative benefit of the graft materials. Furthermore, micro-CT measurements depend on the definition of the volume of interest and the segmentation thresholds used to distinguish bone from residual biomaterial, which may influence the resulting measurements. Finally, differences between the two-dimensional histomorphometric assessment and the three-dimensional micro-CT analysis should be considered when comparing their findings. Despite these limitations, the combined use of micro-CT and histomorphometry provides complementary information on bone formation and residual biomaterial in this experimental model.

5. Conclusions

Within the limitations of this experimental study, both DBBM and β-TCP were associated with substantial bone formation in rabbit tibial defects after 12 weeks. Bone regeneration was also observed in untreated control defects, highlighting the spontaneous healing capacity of this experimental model.

The β-TCP group showed the highest mean values of newly formed bone in both micro-CT and histomorphometric analyses, while histomorphometry revealed a lower mean proportion of residual biomaterial compared with DBBM. However, the differences in newly formed bone between DBBM and β-TCP did not remain statistically significant after adjustment for multiple comparisons. Therefore, the present findings do not establish the superiority of either biomaterial under the experimental conditions evaluated.

Further studies involving larger samples, appropriate statistical models, and multiple evaluation time points are needed to determine whether the observed differences between DBBM and β-TCP represent meaningful differences in bone regeneration and biomaterial remodeling.

Author Contributions: Conceptualization, E.V.-O. and Á.J.-G.; methodology, F.M.-G. and E.V.-O.; software, F.M.-G. and L.M.-G.; validation, M.D.-P. and I.O.-G.; formal analysis, F.M.V. and M.D.-P.; investigation, Á.J.-G.; and J.M.-M.; data curation, F.M.V., I.O.-G.; and J.L.R.-R.; writing—original draft preparation, J.L.R.-R. and E.N.-M.; writing—review and editing, F.M.-G. and E.V.-O.; project administration, I.O.-G.; and J.M.-M.; funding acquisition, L.M.-G.; and E.N.-M. All authors have read and agreed to the published version of the manuscript.

Funding: This research received no external funding.

Institutional Review Board Statement: The animal study protocol was approved by the Ethics Committee for Animal Experimentation of the University of Córdoba, Spain (approval code: 2022PI/40; date of approval: 20 December 2022). All experimental procedures were conducted in accordance with applicable Spanish and European regulations on the protection of animals used for scientific purposes.

Informed Consent Statement: Not applicable.

Data Availability Statement: The original contributions presented in the study are included in the article; further inquiries can be directed to the corresponding authors.

Conflicts of Interest: The authors declare no conflicts of interest.

References

1. Bubalo, M.; Dugonjic, S.; Dubovina, D.; Stojanovic, Z.; Gardasevic, M.; Mijatovic, J.; Milovanovic, B.; Stevic, M.; Stepovic, M.; Jeremic, D.; et al. Bone substitutes in alveolar ridge augmentation: A narrative literature review. *J. Funct. Biomater.* **2026**, *17*, 176. [CrossRef] [PubMed]
2. Barone, A.; Cinquini, C.; Valente, N.A.; Velasco-Ortega, E.; Derchi, G.; D'Amico, E.; Iezzi, G. Alveolar ridge preservation procedures performed with freeze-dried bone allograft: Clinical and histologic outcomes in a case series: Part ii. *Int. J. Periodontics Restor. Dent.* **2024**, *44*, 685–696. [CrossRef] [PubMed]
3. Velasco-Ortega, E.; Valente, N.; Iezzi, G.; Petrini, M.; Derchi, G.; Barone, A. Maxillary sinus augmentation with three different biomaterials: Histologic, histomorphometric, clinical and patient reported outcomes from a randomized controlled trial. *Clin. Impl Dent. Relat. Res.* **2021**, *23*, 86–95. [CrossRef] [PubMed]
4. Zhao, R.; Yang, R.; Cooper, P.R.; Khurshid, Z.; Shavandi, A.; Ratnayake, J. Bone grafts and substitutes in dentistry: A review of current trends and developments. *Molecules* **2021**, *26*, 3007. [CrossRef] [PubMed]
5. Thomas, J.V.; Martande, S.; Meenathathil, J.T.; Bhagat, B.; Pv, S.; Thakur, S.; Suryawanshi, K.; Yein, N. Comparative effectiveness of alloplastic and biologic grafts in maxillary sinus augmentation: A systematic review. *BDJ Open* **2026**, *12*, 46. [CrossRef] [PubMed]
6. Hindocha, M.H.; Iqbal, O.; King, E.M. Bone regeneration techniques for dental implant placement comparing the effect of graft material on bone volume and long-term graft stability: A systematic review. *J. Oral. Implantol.* **2026**, *52*, 213–224. [CrossRef] [PubMed]
7. Madi, M.; Al-Naief, N.S.; Alagl, A.S. Effect of two deproteinized bone graft materials for socket preservation: A clinical and histological study. *Front. Oral. Health* **2025**, *6*, 1630504. [CrossRef] [PubMed]
8. Pezzella, V.; Blasi, A.; Mauriello, L.; Trapanese, G.; Ramaglia, E.; Basilicata, M.; Iorio-Siciliano, V.; Ramaglia, L. Effectiveness of β-tricalcium phosphate for alveolar ridge preservation: A systematic review. *J. Funct. Biomater.* **2026**, *17*, 247. [CrossRef] [PubMed]
9. Galindo-Moreno, P.; Martín-Morales, N.; Olaechea, A.; Hernández-Cortes, P.; Verdugo-Escamilla, C.; Martinez-Ruiz, F.; Carrillo-Galvez, A.B.; O'Valle, F.; Padial-Molina, M. Physico-chemical and biological characterization of a new bovine bone mineral matrix available for human usage. *Clin. Implant. Dent. Relat. Res.* **2023**, *25*, 370–380. [CrossRef] [PubMed]
10. Toledano-Serrabona, J.; Romeu-I.-Fontanet, A.; Gay-Escoda, C.; Camps-Font, O.; Sánchez-Garcés, M.Á. Clinical and histological outcomes of maxillary sinus floor augmentation with synthetic bone substitutes for dental implant treatment: A meta-analysis. *J. Oral. Implantol.* **2022**, *48*, 158–167. [CrossRef] [PubMed]
11. Yao, C.; Pripatnanont, P.; Zhang, J.; Suttapreyasri, S. Fabrication and characterization of a bioactive composite scaffold based on polymeric collagen/gelatin/nano β-TCP for alveolar bone regeneration. *J. Mech. Behav. Biomed. Mater.* **2024**, *153*, 106500. [CrossRef] [PubMed]
12. Bańkosz, M.; Urbaniak, M.M.; Szwed, A.; Rudnicka, K.; Włodarczyk, M.; Drabczyk, A.; Kudłacik-Kramarczyk, S.; Tyliszczak, B.; Sobczak-Kupiec, A. Physicochemical and biological analysis of composite biomaterials containing hydroxyapatite for biological applications. *J. Biomed. Mater. Res. B Appl. Biomater.* **2023**, *111*, 2077–2088. [CrossRef] [PubMed]
13. Inchingolo, A.M.; Marinelli, G.; Trilli, I.; Del Vecchio, G.; Di Noia, A.; Inchingolo, F.; Del Fabbro, M.; Palermo, A.; Inchingolo, A.D.; Dipalma, G. A Histological and clinical evaluation of long-term outcomes of bovine bone-derived xenografts in oral surgery: A systematic review. *J. Funct. Biomater.* **2025**, *16*, 321. [CrossRef] [PubMed]
14. Choy, C.S.; Lee, W.F.; Lin, P.Y.; Wu, Y.F.; Huang, H.M.; Teng, N.C.; Pan, Y.H.; Salamanca, E.; Chang, W.J. Surface Modified β-Tricalcium phosphate enhanced stem cell osteogenic differentiation in vitro and bone regeneration in vivo. *Sci. Rep.* **2021**, *11*, 9234. [CrossRef] [PubMed]
15. Ni, X.; Feng, J.; Liang, M.; Zhou, F.; Xia, Y.; Xia, P. Enhancing bone repair with β-TCP-based composite scaffolds: A review of design strategies and biological mechanisms. *Orthop. Res. Rev.* **2025**, *17*, 313–340. [CrossRef] [PubMed]
16. Velasco-Ortega, E.; Sierra-Baztan, A.; Jiménez-Guerra, A.; España-López, A.; Ortiz-Garcia, I.; Núñez-Márquez, E.; Moreno-Muñoz, J.; Rondón-Romero, J.L.; López-López, J.; Monsalve-Guil, L. Long-term clinical study of implants placed in maxillary sinus floor augmentation using beta-tricalcium phosphate. *Int. J. Environ. Res. Public Health* **2021**, *18*, 9975. [CrossRef] [PubMed]
17. Abd-Allah, M.F.; Gawish, A.S.; El Mekkawi, A.E.R.O.; Abd-Allah, N.F.; Radi, N.A.; Abdel-Rahman, F.M.; Saeidi, A.; Elsayed, S.A.; Mohamed, I.M. Evaluation of bone maturation following application of treated tooth bio-graft in bone defects: Experimental animal study. *Natl. J. Maxillofac. Surg.* **2025**, *16*, 440–446. [CrossRef] [PubMed]
18. Gibson, I.R.; Conway, J.C.; Lopes, V.R.; Oliver, R.; Wang, T.; Wills, D.; Buckland, T.; Walsh, W.R. Bone healing response of two different silicate-containing calcium phosphate synthetic bone grafts in a rabbit femoral critical-sized defect model. *J. Biomed. Mater. Res. B Appl. Biomater.* **2026**, *114*, 70103. [CrossRef] [PubMed]
19. Yaşar, N.Ç.; Ünsal, G.; Kocaelli, H.A.; Orhan, K.; Sağ, F.B. Comparative analysis of local application of titanium-platelet rich fibrin (T-PRF) and leukocyte-platelet rich fibrin (L-PRF) in bone defect healing: A micro-CT and histopathological study in rabbit models. *Microsc. Res. Tech.* **2025**, *88*, 2073–2084. [CrossRef] [PubMed]

20. Abdelmoneim, D.; Coates, D.E.; Schmidlin, P.; Botter, S.; Li, K.C.; Porter, G.C.; Seo, B.; Duncan, W.J. In vivo healing of low temperature deproteinized bovine bone xenograft in a rabbit cranial model. *J. Biomed. Mater. Res.* **2024**, *112*, 1436–1450. [CrossRef] [PubMed]
21. Călin, C.; Dima, O.; Ancuta, D.L.; Coman, C.; Pameijer, C.H.; Paulsen, F.; Sprenger, M.; Nita, T.; Didilescu, A.C. Guided bone regeneration using beta-tricalcium phosphate and leucocyte platelet-rich fibrin versus a novel biodegradable urethane composite in critical-size osseous defects in rabbit tibia: Histologic results of a pilot study. *Ann. Anat.* **2025**, *260*, 152672. [CrossRef] [PubMed]
22. Fujioka-Kobayashi, M.; Urbanova, V.; Lang, N.P.; Katagiri, H.; Saulacic, N. Combined use of deproteinized bovine bone mineral and α-tricalcium phosphate using gelatin carriers. *BMC Oral Health* **2025**, *25*, 275. [CrossRef] [PubMed]
23. Donath, K.; Breuner, G.A. Method for the study of undecalcified bones and teeth with attached soft tissues. The Säge-Schliff (sawing and grinding) technique. *J. Oral Pathol.* **1982**, *11*, 318–326. [CrossRef] [PubMed]
24. Laczkó, J.; Levai, G. A simple differential staining method for semithin sections of ossifying cartilage and bone tissues embedded epoxy resin. *Mikroskopie* **1975**, *31*, 1–4.
25. Li, J.; Qu, Y.; Chu, B.; Wu, T.; Pan, M.; Mo, D.; Li, L.; Ming, Y.; Yang, Y.; Wang, M.; et al. Research progress on biomaterials with immunomodulatory effects in bone regeneration. *Adv. Sci.* **2025**, *12*, 01209. [CrossRef] [PubMed]
26. Thirumalaivasan, N. Collagen-composite scaffolds for alveolar bone and dental tissue regeneration: Advances in material development and clinical applications-a narrative review. *Dent. J.* **2025**, *13*, 396. [CrossRef] [PubMed]
27. Yasser, S.; Mohammed, A.A.A.R.; El-Safty, S.; Shon, A.; Al-Gabri, R.S.; Alqutaibi, A.Y.; Fouad, H.; Saleh, R.G. Comparing the effect of using calcified autogenous nano dentin particles versus micro dentin particles in the healing of mandibular bony defects in New Zealand rabbits. *BMC Res. Notes* **2025**, *18*, 125. [CrossRef] [PubMed]
28. Khan, A.A.; Wang, Y.; Li, H.; Zhang, X.; Zhang, X.; Zhang, X.; Li, X. Combined synergistic effects of concentrated growth factors and adipose-derived mesenchymal stem cells on regeneration of induced mandibular defects in rabbits. *Cytotherapy* **2025**, *27*, 483–492. [CrossRef] [PubMed]
29. Elmeshreghi, T.N.; El-Seddawy, F.D.; Gomaa, M.; Raouf, M.A.E.; Ezzeldein, S.A. The impact of autogenous bone grafts on the regeneration of radial bone defects in rabbits compared to autogenous advanced platelet-rich fibrin plus. *Open Vet. J.* **2025**, *15*, 325–338. [CrossRef] [PubMed]
30. Lee, S.; Jung, J.; Lee, J.; Ko, Y.C.; Lee, D.; Koo, K.T.; Seol, Y.J.; Lee, Y.M. Bone regeneration and biosorption patterns of different bone substitutes: An in vivo study in rabbit skulls. *J. Periodontal Implant. Sci.* **2024**, *55*, 191–205. [CrossRef] [PubMed]
31. Hussein, N.; Nayak, V.V.; Dharmaraj, N.; Mirsky, N.A.; Norton, W.; Ramagli, L.; Tailor, R.; Kasper, F.K.; Coelho, P.G.; Witek, L.; et al. A Compromised maxillofacial wound healing model for characterization of particulate bone grafting: An in vivo study in rabbits. *J. Biomed. Mater. Res. B Appl. Biomater.* **2025**, *113*, e35556. [CrossRef] [PubMed]
32. Cetin Genc, C.; Yılmaz-Dagdeviren, H.D.; Deniz, Y.; Derkus, B.; Degirmenci, A.; Arslan, Y.E. Unveiling bone and dental regeneration potential of quince seed mucilage-nanohydroxyapatite scaffolds in rabbit mandibles. *J. Biomed. Mater. Res. B Appl. Biomater.* **2025**, *113*, e35570. [CrossRef] [PubMed]
33. Botticelli, D.; Lang, N.P. Dynamics of osseointegration in various human and animal models-a comparative analysis. *Clin. Oral. Impl Res.* **2017**, *28*, 742–748. [CrossRef] [PubMed]
34. Schmitz, J.P.; Hollinger, J.O. The critical size defect as an experimental model for craniomandibulofacial nonunions. *Clin. Orthop. Relat. Res.* **1986**, *205*, 299–308. [CrossRef]
35. Brunello, G.; Panda, S.; Schiavon, L.; Sivolella, S.; Biasetto, L.; Del Fabbro, M. The Impact of Bioceramic Scaffolds on Bone Regeneration in Preclinical In Vivo Studies: A Systematic Review. *Materials* **2020**, *13*, 1500. [CrossRef] [PubMed]
36. Alpman, U.; Atalan, G.; Karaca, E.; Perk, G. The comparison of the applicability of low-frequency laser, β-tricalcium phosphate, platelet-rich fibrin, and bone marrow in the treatment of tibial fractures in rabbits. *Acta Cir. Bras.* **2025**, *40*, 407525. [CrossRef] [PubMed]

Disclaimer/Publisher's Note: The statements, opinions and data contained in all publications are solely those of the individual author(s) and contributor(s) and not of MDPI and/or the editor(s). MDPI and/or the editor(s) disclaim responsibility for any injury to people or property resulting from any ideas, methods, instructions or products referred to in the content.